

## Alpha- 1 Antitrypsin Deficiency (AATD) in Children: Pulmonary Involvement

Mohammad Esmaeili<sup>1</sup>, \*Marjan Esmaeili<sup>2</sup>, Seyed Javad Sayedi<sup>3</sup>, Mohammad Ali Kiani<sup>1</sup>

<sup>1</sup> Associated Professor of Pediatrics, Mashhad University of Medical Sciences, Mashhad, Iran.

<sup>2</sup> Resident of Pediatrics, Iran University of Medical Sciences, Tehran, Iran.

<sup>3</sup> Assistant Professor of Pediatrics, Mashhad University of Medical Sciences, Mashhad, Iran.

### **Abstract**

#### **Introduction**

Alpha-1 Antitrypsin Deficiency (AATD) is one of the most common genetic disorders in white race, a usual cause of liver disease in children, and hepatopulmonary involvement in children and adult. The aim of this case description is presenting a child with early lung disease without liver parenchymal disorder.

#### **Case presentation**

We describe a 13 year old boy because of exertional dyspnea, wheezing, productive cough and repeated hospital admission due to bronchopneumonia. There was no immune deficiency, sinusitis and allergic lung disease. There was no history of foreign body aspiration. Cystic fibrosis cause ruled out. Protein electrophoresis and serum level alpha1-AT evaluation documented alpha1-ATD. The patient was treated with conservative management.

#### **Conclusion**

This article suggests that if a child presents with chronic pulmonary symptoms, possibility of alpha1-ATD should be considered and worked up.

**Keywords:** AATD, Alpha1-antitrypsin deficiency, Bronchiectasis, Children, Emphysema.

---

#### **\* Corresponding Author:**

Marjan Esmaeili, MD, Resident of Pediatrics, Iran University of Medical Sciences, Tehran, Iran.  
Email: Esmaeili\_82@Yahoo.com

Received date: Jan 11, 2014 ; Accepted date: Jan 22, 2015

## Introduction

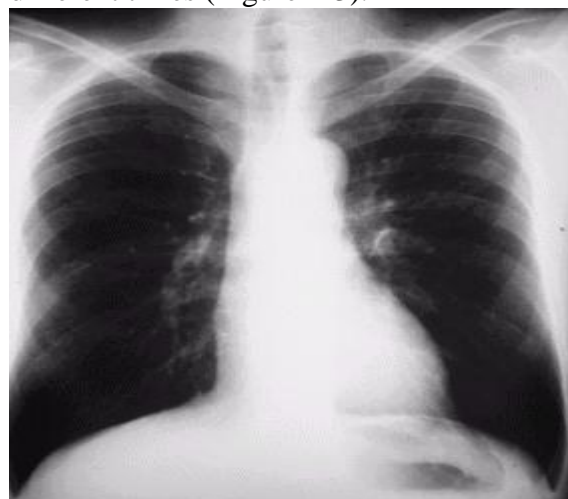
Alpha1-antitrypsin (A1-AT) deficiency is one of the most common hereditary disorders among Caucasians, characterized by reduced level or absence of serum alpha1-AT and is a high risk for developing pulmonary emphysema and/or liver disease (1). Although alpha1-AT is an important cause of emphysema in 3<sup>rd</sup> and 4<sup>th</sup> decade of life and a usual cause of liver disease in children, but it may causes pulmonary disease in children. Alpha1-AT is a glycoprotein produced by the liver. Its primary function is to protect the lungs tissue from proteolytic enzymes released from dead bacteria or leukocytes in the lung. Protease concentration of the leukocytes may be an important factor in severity of pulmonary disease with a given level of alpha1-AT (2, 3).

Aim of this article is reporting a 13- year-old boy with alpha1-AT deficiency that presented with chronic bronchopulmonary involvement and repeated hospital admission without apparently liver parenchymal disorder.

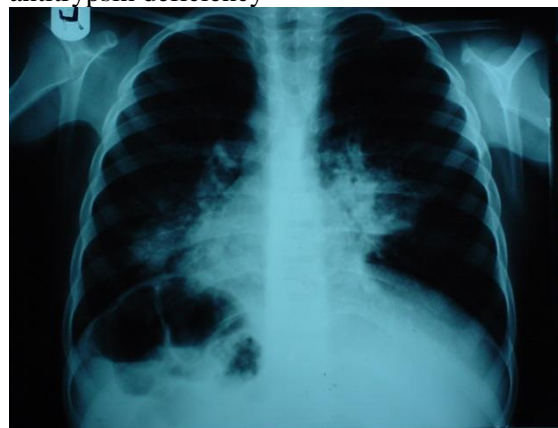## Case presentation

The patient was a 13 years old male child of second degree consanguineous parents who was admitted to emergency ward of Dr. Sheikh Hospital presented with respiratory distress, fever, productive cough predominantly in lying down position from one week ago. He had history of recurrent bronchopneumonia from about 5 years ago with repeated hospital admission and conservative management with several courses antibiotic and mucolytic therapy. He had history of exertional dyspnea from sometimes ago. He was a boy with normal birth weight, however sever failure to thrive, anorexic and malnourished at this time. There was no history of foreign body aspiration. He had no history of chronic diarrhea or any features of hepatic and enteral problem. His weigh was 18.300 kg, height 111cm, head circumference 51cm,

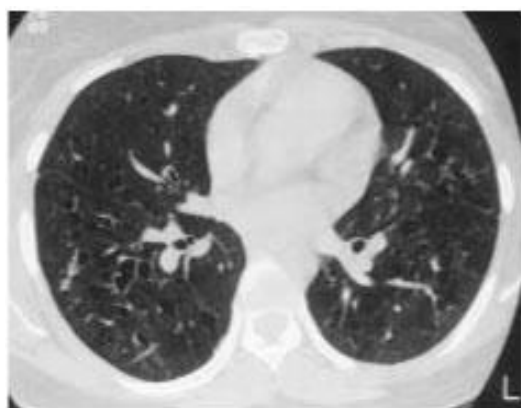cooperative and mentally normal. He had tachypnea (Respiratory rate; 43), pulse rate: 96, body temperature: 38.8, examination of oronasopharyngeal suction was normal. Chest appeared normal apparently. In auscultation there were bilateral course crepitations and generalized wheezing in both lungs. Sinuses X-ray was normal but only mild opacity of left maxillary sinus. Chest X-ray showed diffuse emphysema and pulmonary hilar infiltration and cystic bronchiectasis. An High-resolution computed tomography (HRCT) scan showed bilateral bronchiectasis with pulmonary fibrosis. There was no evidence of foreign body or lymphadenopathy. The following figures show some of images that were taken from the patient in different times (Figure 1-3).



**Fig.1:** Emphysema in our patient with alpha1-antitrypsin deficiency



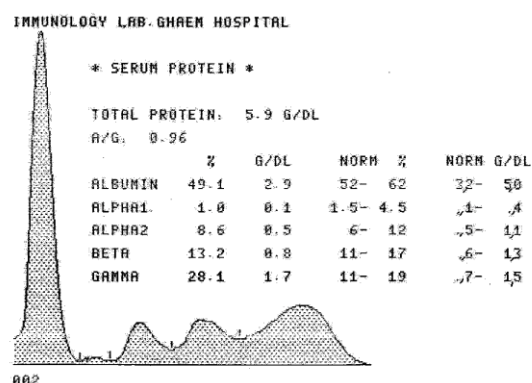
**Fig.2:** Emphysema and bronchiectasis in patient with AATD



**Fig.3:** HRCT shows bronchiectasis in patient with alpha1-antitrypsin deficiency

Hemogram showed: White blood cell count (WBC): 26300, Neutrophil count: 62%, Lymphocyte: 36%, Eosinophil: 2%, BUN: 10.8, Creatinin: 0.65, Serum glutamic-oxaloacetic transaminase (SGOT): 12, Serum glutamic pyruvic transaminase (SGPT): 58, Alkaline phosphatase (ALP): 230, Calcium: 9.6, Phosphorus (P): 3.8, Sodium(Na):145, Potassium (K):4, Prothrombin time (PT):14, Partial thromboplastin time (PTT): 46, Serum Albumine: 5.18gr/dl, Alpha-1-globulin: 0.05gr/dl, Alpha-2-globulin: 0.7gr/dl, Beta globulin: 1.27gr/dl, Gamma globulin: 2.8gr/dl, Albumin to globulin (A/G) ratio: 1.08, Immunoglobulin G (IgG):1300mg/dl, Immunoglobulin A (IgA): 210mg/dl, Immunoglobulin M (IgM): 105mg/dl, Arterial blood gas (ABG)= (P<sub>O2</sub>) Oxygen partial pressure (tension): 78mmHg, Oxygen saturation (O<sub>2</sub>-Sat): 85.7%, PH: 7.31, Partial pressure of carbon dioxide (P<sub>CO2</sub>): 24.6mmHg, Bicarbonate (HCO<sub>3</sub>): 12.1, 5 unit Purified protein derivative (PPD) test: 4mm diameter, sweat chloride test: Na: 44, Chloride (Cl): 52. Serum alpha1-AT level: 18mg/dl. Profile of serum protein electrophoresis is shown in (Figure.4). Sputum was negative for acid fast bacillus. Bronchoscopy showed evidence of bilateral bronchiectasis with profuse sputum. Family history was negative for tuberculosis or allergic

respiratory disease. His father was cigarette smoker for long time.



**Fig.4:** Pattern of protein electrophoresis in our patient with alpha1-antitrypsin deficiency

## Discussion

Alpha1-ATD was first identified in 1963, together with its association with the inherited form of early onset of severe lower zone panacinar emphysema. Alpha1-AT is synthesized in the liver and protects lung alveolar tissues from destruction by neutrophil elastase and other proteases (4, 5).

Alpha1-ATD is a common autosomal recessive condition (1:1600 to 1:1800) in which liver disease results from retention of abnormal polymerized Alpha1-AT in the endoplasmic reticulum of hepatocytes, and emphysema results from alveolar wall damage (6).

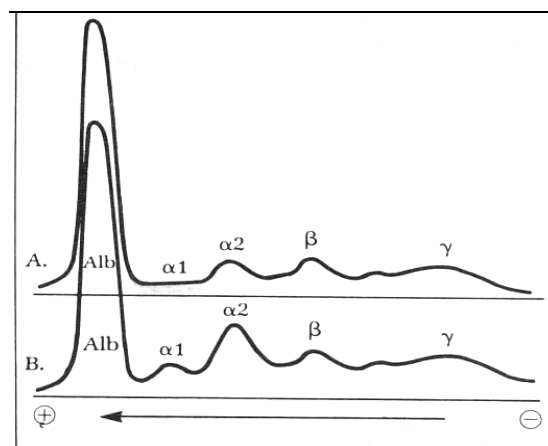
Alpha1-AT constitutes about a 95% of all the antiprotease activity in human alveoli, and neutrophil elastase is considered the protease largely responsible for alveolar destruction (7).

The clinical consequences of alpha1-ATD in childhood might be presented as neonatal jaundice, cholestasis, chronic liver disease; hemorrhagic disease and sometimes lung disease, membrano-proliferative glomerulonephritis, panniculitis, necrotizing vasculitis and early onset emphysema especially in smokers are associations with alpha1-ATD in adult life (8, 9).

Alpha1-ATD is one of the 3 most common lethal genetic disorder as cystic fibrosis and down syndrome. It affects mainly Caucasians (whites) from northern Europe. New data were presented, demonstrating that it is a Worldwide racial and ethnic distribution, found in various populations of African blacks, Arabs, Jews in The Middle East, Central, Far East and Southeast Asians, as well as whites in Australians, Europe, New Zealand and North America. In a total population of 4.4 billion in the 58 countries surveyed, there are at least 116 million carriers (with Pi phenotypes PiSZ and PiMZ) and 3.4 million with deficiency of alleles combinations (phenotypes PiSS, PiSZ) for the two most prevalent deficiency alleles PiS and P1Z (10, 11). In our country there is no documental prevalence of this disorder (8, 12, 13).

Alpha1-ATD should be considered in differential diagnosis of chronic pulmonary disease in childhood, obstructive Jaundice in the newborn, cirrhosis in children and adults, familial early onset obstructive lung disease in adult, and combined pulmonary and hepatic disease in childhood and adolescence. It is the most common genetic cause of liver disease and second indication of liver transplantation after than biliary atresia in children (14-16). Alpha1-ATD demonstrates the interaction of inflammation with environmental infectious and toxic risk factors and the notion that chronic lung or liver disease in adults may have their origins in childhood, therefore progression may be hated if appreciated in their early phases (13, 17).

Alpha1-AT a glycoprotein, synthesized by liver hepatocytes and is found in most biologic fluids. It accounts for 90% of the area under the  $\alpha 1$  peak in serum protein electrophoresis and is responsible for 80 – 90% of serum trypsin inhibitory capacity. Pattern of protein electrophoresis in a normal subject and a patient with  $\alpha 1$ -ATD is shown in (Figur.5).



**Fig.5:** Pattern of protein electrophoresis in a normal child and a patient with AATD

Name of alpha1-AT derived from protease inhibitor (Pi) activity including elastase, proteases, collagenase, chymotrypsin, plasmin and thrombin. Alpha1-AT is an acute phase reactant, serum levels rising in response to infection, inflammation and stress (8, 18, 19).

Anti elastase activity protects elastin fibers of pulmonary tissue from proteolytic action of elastase like enzymes that are released from leukocytes and macrophages during process of natural decay or inflammation resulting from a variety insults. A deficiency or decreased serum level is of alpha1-AT activity is due to altered configuration of alpha1-AT molecule that prevents its release from hepatocytes, contribute to accelerated and even irreversible tissue damage. Not all alpha1-AT deficient individuals develop pulmonary disease strongly suggest other exogenous and endogenous risk factors variance in this disorder (15, 20).

The serological expression (phenotype) alpha1-AT is inherited as two autosomal codominant allele (genotype) of which there are nearly 24 allelic Pi variants, characterized by their elecrophoretic mobility in starch and polyacrylamide gels. Serum level of alpha1-AT is under genetic control as determined by the serum Pi type. Profound  $\alpha 1$ -ATD (PiZZ with serum level 10-20% those of PiMM) should be suspected when there is low or flat alpha

region on simple protein electrophoresis. The diagnosis of alpha1-ATD is based on altered migration of abnormal alpha1-AT molecule in serum specimens subjected to isoelectric focusing and analysis (15, 18, 21). The phenotype should be determined in all suspected cases.

The most common allele is M (PiM) and homozygous individuals (MM) produce normal amounts of  $\alpha$ 1 antitrypsin (serum levels 150-350mg/dl). The most common form of alpha1-ATD is associated with allele Z, or homozygous PiZ (ZZ). Serum levels of  $\alpha$ 1-AT in these patients are about 10-15% of normal serum levels. Patients with PiSZ and those with the null gene (no produce any alpha1-AT) are high risk for early onset lung destruction. Serum levels less than 80mg/dl suggest significant risk for lung disease (4, 16). Our case had nearly flat  $\alpha$  segment of protein electrophoretic profile of his serum and low level (18mg/dl) of serum alpha1-AT.

Pulmonary involvement presents as slowly progression dyspnea, though many patients initially have symptoms of cough or sputum production and wheezing due to progressive panacinar emphysema and bronchopulmonary destructive inflammatory process, evidenced by increased basilar lucency and infiltrative changes on chest X-ray. As the disease progress, chronic cough exercise intolerance, chronic bronchitis and bronchiectasis add to clinical picture. Cigarette smoking and air pollutants definitely contribute to early onset presentation. Although pulmonary involvement usually presents in the third decades of life, due to clinical case variability and genetic variants, our case presented with pulmonary disease in childhood (22-24).

Treatment involves bronchodilation, physical rehabilitation, smoking cessation and intravenous augmentation therapy with alpha1-AT, aggressive treatment of pulmonary infection, routine use of

pneumococcal, influenza vaccine and lung transplantation (4, 25-29).

Conservative management advised and was done in our patient with marked improvement. Augmentation therapy with alpha1-AT was not available in our facility set. Phenotyping is required to confirm alpha1-ATD. More than 100 variants of ATD have been identified but only one phenotype, PiZZ is responsible for nearly all cases of ATD emphysema and liver disease. SERPINA I gene that formerly known as Pi is located in the long arm of chromosome 14. Chest X- ray, liver function tests, sweat chloride test, serum protein and immune electrophoresis and high resolution computerised tomography (CT) of chest might be required for definitive diagnosis and evaluation (3, 9).

### Conclusion

This article suggest that if a child presents with chronic or repeated bronchopulmonary signs and lung destructive disorder, alpha1-AT work up should be done as same as the children present with cholestatic and or chrome liver disease.

**Conflict of interests:** None.

### References

1. Seyama K. State of alpha1-antitrypsin deficiency in Japan. *Respirology* 2001; 6 (Suppl): S35-8.
2. Winnie GB and Boas SR. alpha1-antitrypsin deficiency and emphysema. In: Kliegman RM, Stonton BF, Geme ST, Schor, Behrman RE,. *Nelson textbook of pediatrics*. 19<sup>th</sup> ed. Elsevier-Saunders 2011; 1462-63.
3. Hunt JM1, Tuder R. Alpha 1 anti-trypsin: one protein, many functions. *Curr Mol Med* 2012; 12(7):827-35.
4. Stockley RA. Alpha-1-antitrypsin deficiency: what next? *Thorax* 2000; 55(7):614-8.
5. James K. Stoller and Loutfi S. Aboussouan "A Review of  $\alpha$ 1-Antitrypsin Deficiency", *American Journal of*

- Respiratory and Critical Care Medicine 2012; 185(3):246-59.
6. Primhak RA, Tanner MS. Alpha-1 antitrypsin deficiency. *Arch Dis Child* 2001; 85(1): 2-5.
  7. Silverman GA, Pak SC, Perlmutter DH. Disorders of protein misfolding: alpha-1-antitrypsin deficiency as prototype. *J Pediatr*. 2013;163(2):320-6.
  8. Jeffrey H. Teckman, Douglas Lindblad. Alpha-1-antitrypsin deficiency: Diagnosis, pathophysiology, and management. *Current Gastroenterology Reports* 2006; 8(1):14-20.
  9. Ricardo Valverde, Belén Rosales, Francisco Javier Ortiz-de Frutos, José Luis Rodríguez-Peralto, Pablo L. Ortiz-Romero. Alpha-1-Antitrypsin Deficiency Panniculitis. *Dermatologic Clinics* 2008; 26(4):447-451.
  10. De Serres FJ. Alpha-1 antitrypsin deficiency is not a rare disease but a disease that is rarely diagnosed. *Environ Health Perspect* 2003; 111(16):1851-4.
  11. De Serres FJ. Worldwide racial and ethnic distribution of alpha1-antitrypsin deficiency: summary of an analysis of published genetic epidemiologic surveys. *Chest* 2002; 122(5):1818-29.
  12. Justin Raney, James K. Stoller. A Review of Alpha-1 Antitrypsin Deficiency. *Semin Respir Crit Care Med* 2005; 26(2):154-66.
  13. Fregonese L, Stolck J. Hereditary alpha-1-antitrypsin deficiency and its clinical consequences. *Orphanet J Rare Dis* 2008; 3: 16.
  14. Loreno M, Boccagni P, Rigotti P, Naccarato R, Burra P. Combined liver-kidney transplantation in a 15-year-old boy with alpha1-antitrypsin deficiency. *J Hepatol* 2002; 36(4):565-8.
  15. Perlmutter DH. Alpha1-antitrypsin deficiency. *Current Treatment Options in Gastroenterology* 2000, 3(6):451-6.
  16. Bakula A, Socha P, Pawlowska J, Teisseyre M, Jankowska I, Kalicinski P. Good and bad prognosis of alpha-1-antitrypsin deficiency in children: when to list for liver transplantation. *Transplant Proc* 2007; 39(10):3186-8.
  17. Janciauskiene S, Wallmark A, Piitulainen E, Köhnlein T, Welte T, Sveger T. Performance of enhanced liver fibrosis plasma markers in asymptomatic individuals with ZZ  $\alpha$ 1-antitrypsin deficiency. *Eur J Gastroenterol Hepatol* 2011; 23(8):716-20.
  18. Ziai M. Alpha1-antitrypsin deficiency. In: bedside pediatrics. 1<sup>st</sup> ed. Little Brown & Company. Boston 1983; 277-83.
  19. Kyrsten D Fairbanks, Anthony S Tavill. Liver Disease in Alpha 1-Antitrypsin Deficiency: A Review. *The American Journal of Gastroenterology* 2008; 103(8):2136-41.
  20. Linda P. O'Reilly, David H. Perlmutter, Gary A. Silverman, Stephen C. Pak. A1-Antitrypsin deficiency and the hepatocytes – An elegans solution to drug discovery. *Int J Biochem Cell Biol* 2014; 47:109-12.
  21. Köhnlein T, Welte T. Alpha-1 Antitrypsin Deficiency: Pathogenesis, Clinical Presentation, Diagnosis, and Treatment. *Am J Med* 2008; 121(1):3-9.
  22. Palma-Carlos AG, Palma-Carlos ML. Alpha-1-antitrypsin deficiency asthma and allergy. *Eur Ann Allergy Clin Immunol* 2007; 39(4):127-32.
  23. Eden E. Asthma and COPD in alpha-1 antitrypsin deficiency. Evidence for the Dutch hypothesis. *COPD* 2010; 7(5):366-74.
  24. Sandhaus RA, Barker AF, Brantly ML, Eden E, McElvaney NG, Rennard S, et al. Determinants of airflow obstruction in severe alpha-1-antitrypsin deficiency. *Thorax* 2007; 62(9):806-13.
  25. MacDonald D, Joanne L, Cary E. Pathophysiology and treatment of alpha sub 1 -antitrypsin deficiency. *American Journal of Health-System Pharmacy* 1995; 52(5):481-9.
  26. Tanash HA, Riise GC, Hansson L, Nilsson PM, Piitulainen E. Survival benefit of lung transplantation in individuals with severe  $\alpha$ 1-anti-trypsin deficiency (PiZZ) and emphysema. *J Heart Lung Transplant* 2011; 30(12):1342-7.

27. Stockley RA, Parr DG, Piitulainen E, Stolk J, Stoel BC, Dirksen A. Therapeutic efficacy of alpha-1 antitrypsin augmentation therapy on the loss of lung tissue: an integrated analysis of 2 randomised clinical trials using computed tomography densitometry. *Respire Res* 2010; 11(1): 136.

28. Stockley RA, Miravittles M, Vogelmeier C; Alpha One International Registry (A.I.R.). Augmentation therapy for alpha-1 antitrypsin deficiency: towards a personalised approach. *Orphanet Journal of Rare Diseases* 2013; 8:149.