

Congenital Hypertrophic Pyloric Stenosis: A Case Report

Mehdi Foroughi¹, *Zahra Beizavi², Razieh Sadat Mousavi-Roknabadi³

¹MD, Pediatric Surgery Specialist, Department of Pediatric Surgery, Namazee Hospital, Shiraz University of Medical Sciences, Shiraz, Iran.

²MD, General Surgery Specialist, Department of General Surgery, Shiraz University of Medical Sciences, Shiraz, Iran.

³MD, Community Medicine Specialist, Emergency Medicine Department, Shiraz University of Medical Sciences, Shiraz, Iran.

Abstract

Background

Hypertrophic pyloric stenosis (HPS) is a common surgical condition in infancy, and typically presents at 2-4 weeks of age.

Case Presentation

A full term male neonate in Zeinabieh hospital, Shiraz, Iran was presented with oral feeding intolerance from birth, bile-stained output of nasogastric tube, and a double bubble sign on abdominal radiography suspected to duodenal atresia. However subsequent laparotomy on 3rd day of life revealed HPS.

Conclusion

HPS should be considered as part of a rare differential diagnosis of newborn with sign of obstruction at birth.

Key Words: Congenital, Hypertrophic Pyloric Stenosis, Newborn.

*Please, cite this article as Foroughi M, Beizavi Z, Mousavi-Roknabadi ZS. Congenital Hypertrophic Pyloric Stenosis: A Case Report. Int J Pediatr 2020; 8(6): 11467-471. DOI: **10.22038/ijp.2019.44013.3654**

*Corresponding Author:

Zahra Beizavi, MD, General Surgery Resident, Department of General Surgery, Shiraz University of Medical Sciences, Shiraz, Iran. Address: General Surgery Ward Office, Faghihi Hospital, Zand Ave., Shiraz, Iran. Postal Code: 7134844119. Tel: +98 9173014584.

Email: Zahra.beizavi@gmail.com

Received date: Dec.17, 2019; Accepted date: Feb.22, 2020

1- INTRODUCTION

Although Hypertrophic pyloric stenosis (HPS) is the common cause of surgery, next to inguinal hernia, during the first month months of life, its etiology is still unknown and it is likely to be multifactorial, involving genetic predisposition and environmental factors (1). HPS usually affects children between the second and fourth week of life, with a striking male preponderance (2). There are a few reports of infants with oral feeding intolerance and vomiting at birth, which ultimately hyperplasia of smooth muscle fiber of pylorus was observed intraoperatively and most of them were not associated with any other congenital malformation (3, 4).

In 1907, the earliest reported HPS was demonstrated on an autopsy of a 7- month-old fetus (5), after that at least ten well-documented cases of HPS with vomiting and food intolerance from birth were reported (6). This is a report of a newborn with oral feeding intolerance and bile-stained nasogastric tube drainage at birth with a final diagnosis of HPS. This case report along with a few others suggests antenatal development of HPS with a congenital cause that effects on the gastric pyloric muscle fibers.

2- CASE REPORTS

A 4-day-old male neonate was born at 37 weeks gestational age, weighting 2000 grams on October 22, 2017 in Zeinabieh

hospital, Shiraz, Iran. He was delivered by cesarean section to a 34-year-old uncomplicated mother. The antenatal period was uneventful and family history was non-contributory. Apgar scores were 8 and 9 at 1 and 5 min, respectively. Patient was not able to tolerate oral feeding. After insertion of nasogastric tube, a bile-stained output was removed. Laboratory studies revealed mild hypokalemia and mild metabolic alkalosis, while other biochemical and hematologic measurements were normal. Abdominal X-Ray revealed double bubble sign in favor of duodenal atresia (**Figure.1**), clinical examination was unremarkable and no mass was palpable in the abdomen. Next, the patient was transferred to a pediatric surgery center suspecting to duodenal atresia on the 3rd. day of life.

After reevaluation, the patient underwent operation in view of the possibility of anatomical pathology causing persistent obstruction. Abdomen was opened via a supra umbilical incision. After delivery of distal of stomach into the wound, an elongated and thickened pylorus was observed (**Figure.2**). Other site of gastrointestinal tract including duodenum was normal. Hence, an extra mucosal Fredet-Ramstedt pyloromyotomy was performed on 25 October, 2017. The patient tolerated oral feeds postoperatively, and was discharged on the 3rd postoperative day. The informed consent of the patients was taken to report this case report.

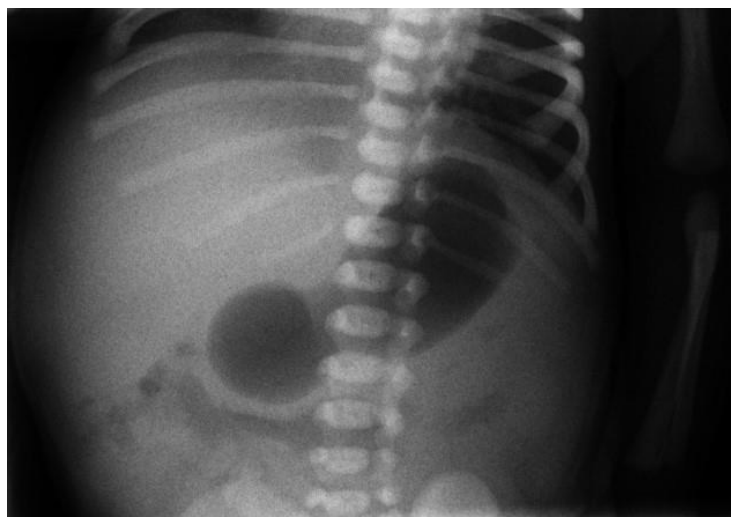


Fig.1: Abdominal radiography in the 3rd day of life is suspected to double bubble sign.

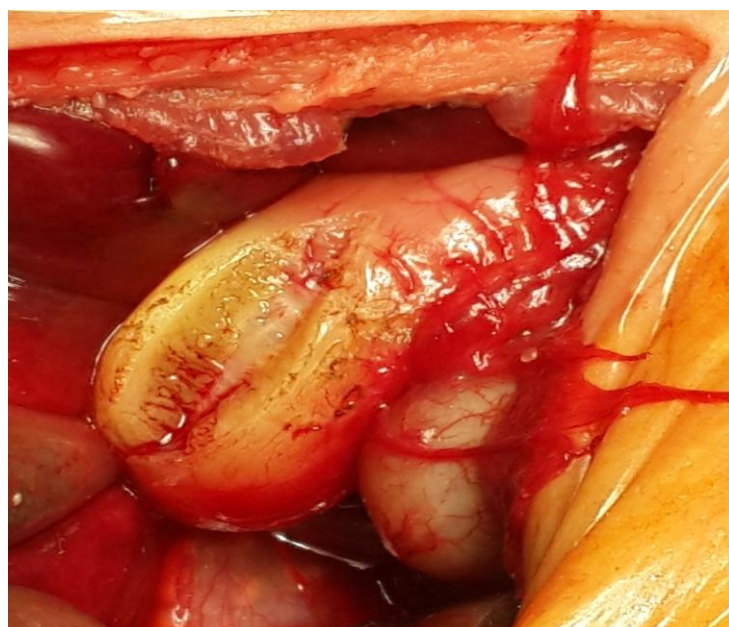


Fig.2: Hypertrophy and hyperplasia of the muscular layers of pylorus was seen intraoperatively.

3- DISCUSSION

HPS is a common cause of surgery during infancy with prevalence of 2-8 per 1000 live births (7). Its etiology is still not fully understood. It seems that there is genetic, familial and environmental predisposition factors required for the development of HPS (8). Typically, HPS presents between the 2nd and 4th week of life. Occasionally a palpable mass in the mid-epigastrium and a hypochloremic,

hypokalemic metabolic alkalosis in laboratory tests are detected. Abdominal radiography mostly shows gastric dilatation (9). This condition results from interaction of a dominant gene of low penetrance and a multifactorial background such as environmental and maternal etiology (10). There are some reports of HPS in infants during the newborn period with vomiting and oral feeding intolerance at birth, which were

diagnosed just at the time of surgery. The youngest patient was a 7-month fetus with pyloric stenosis demonstrated in autopsy (11). Tashjan et al. reported a case of HPS in utero in which prenatal ultrasonography revealed a grossly distended stomach. After birth patient developed nonbilious vomiting and upper gastrointestinal study shows markedly delayed gastric emptying. HPS was diagnosed on the 2nd day of life intraoperatively (12). In this case, typical diagnostic criteria of HPS that was established previously was not observed.

We reported a newborn with oral feeding intolerance at birth and bile-stained nasogastric tube drainage. Physiologically, bilious vomiting should not be observed in a hypertrophied pylorus since it prevents backflow of bile into the stomach, but the presence of bile in the vomit does not exclude HPS as an etiology of vomiting in infants (3). Eyal et al. reported a case of HPS with bilious vomiting without additional gastrointestinal pathology. They stated this might have been due to early diagnosis in infants with smaller thickness measurements of the pylorus, with not fully obstructed stomach and suggested that it might be a congenital etiology in development of HPS (13). Abdominal X-ray revealed a double-bubble sign, which suggests duodenal atresia.

A study reported that only 44% of infants with bilious vomiting who underwent operation had specific findings in abdominal radiography (14). Takahashi et al. observed pylorus opening with occasional passage of the gastric content in a patient with significant hypertrophy of the pylorus, in accordance with the patient's clinical course. They remarked that, imaging might not be reliable enough because of disease atypical manifestations. Although these patients are symptomatic since birth, few of them underwent operation within the 1st week of life. This might be related to the low suspicion of this condition in a newborn (8). Moreover,

early diagnosis will help to shorten the duration of hospital stay and improve the prognosis of HPS. In addition, reduced hospitalization will depend on earlier operation on patients with normal electrolyte indices at the early stage of disease (15). Current guideline might not be sufficient for diagnosis of HPS in newborn because of thin pyloric muscle thickness, equivocal clinical finding, and electrolyte variants (16).

4- CONCLUSION

This report of early presentation of HPS suggests its congenital etiology. Also, it is notable that whenever a newborn is not tolerating feed at birth, HPS should also be considered as a rare differential diagnosis, even if typical symptoms are lacking.

5- CONFLICT OF INTEREST: None.

6- REFERENCES

1. Panteli C. New insights into the pathogenesis of infantile pyloric stenosis. *Pediatr Surg Int.* 2009; 25:1043–52.
2. Shaoul R, Enav B, Steiner Z, Mogilner J, Jaffe M. Clinical presentation of pyloric stenosis: the change is in our hands. *Isr Med Assoc J.* 2004; 6(3):134-7.
3. Piroutek MJ, Brown L, Thorp AW. Bilious vomiting does not rule out infantile hypertrophic pyloric stenosis. *Clin Pediatr (Phila).* 2012; 51(3):214-8.
4. Sinha CK, Gangopadhyay AN, Sahoo SP, Gopal SC, Gupta DK, Gupta BB. Congenital hypertrophic pyloric stenosis at birth. *Indian J Pediatr.* 1996; 63(3):413-4.
5. Dent C. Hypertrophic pyloric stenosis in infants. *Br Med.* 1907;1: 627–28.
6. Ng WT, Lee SY. Hypertrophic pyloric stenosis, congenital or not congenital: a critical overview. *Pediatr Surg Int.* 2002; 18(5-6):563-4. Epub 2002 Sep 12.
7. Stark CM, Rogers PL, Eberly MD, Nylund CM. Association of prematurity with the development of infantile hypertrophic pyloric stenosis. *Pediatr Res.* 2015; 78:218-22.

8. Takahashi T, Sato Y, Yamazaki T, Hayashi A, Okamoto T. vomiting in infant with congenital nephrotic syndrome: Answers. *Pediatr Nephrol.* 2017; 32(9):1521-23.
9. Zhu J, Zhu T, Lin Z, Qu Y, Mu D4. Perinatal risk factors for infantile hypertrophic pyloric stenosis: A meta-analysis. *J Pediatr Surg.* 2017; 52(9):1389-97.
10. Ranells JD, Carver JD. Infantile hypertrophic pyloric stenosis: epidemiology, genetics, and clinical update. *Adv Pediatr.* 2011; 58(1):195-206.
11. Chan SM, Chan EK, Chu WC, et al. Hypertrophic pyloric stenosis in a newborn: a diagnostic dilemma. *Hong Kong Med J.* 2011; 17(3):245-7.
12. Tashjian DB, Konefal SH. Hypertrophic pyloric stenosis in utero. *Pediatr Surg Int.* 2002; 18(5-6):539-40.
13. Eyal O, Asia A, Yorgenson U, Nagar H, Schpirer Z. Atypical infantile hypertrophic pyloric stenosis. *Harefuah.* 1999; 136(2):113-4, 175.
14. Morrison SC. Controversies in abdominal imaging. *Pediatr Clin North Am.* 1997; 44(3):555-74.
15. Andrassy RJ, Haff RC, Larsen GL. Infantile hypertrophic pyloric stenosis during the first week of life. Approaches to diagnosis, based on observations of a newborn whose vomiting began on the first day. *Clin Pediatr (Phila).* 1977; 16(5):475-6.
16. Leaphart CL, Borland K, Kane TD, et al. Hypertrophic pyloric stenosis in newborns younger than 21 days: remodeling the path of surgical intervention. *J Pediatr Surg.* 2008; 43(6): 998–1001.