

A Case of Pulmonary Foreign Body Reviewed as Mass

Sayed Javad Sayedi¹, Reza Shojaeian², Maliheh Bani Hassan³, *Ali Khakshour⁴

¹Assistant Professor of Pediatric Pulmonology, Dr. Sheikh Hospital, Mashhad University of Medical Sciences, Mashhad, Iran. ²Assistant Professor of Pediatric Surgery, Dr. Sheikh Hospital, Mashhad University of Medical Sciences, Mashhad, Iran. ³Resident of Pediatrics, Dr. Sheikh Hospital, Mashhad University of Medical Sciences, Mashhad, Iran. ⁴Assistant Professor of Pediatric, Dr. Sheikh Hospital, Mashhad University of Medical Sciences, Mashhad, Iran.

Abstract

Foreign Body Aspiration (FBA) is a common and sometimes life-threatening problem in children and in higher age groups. FBA highest incidence rate is during the second year in children and the sixth decade of life in adults, and often foreign bodies due to their shape and size pass through larynx and trachea and place in bronchi. The most common aspirated body by children are nuts. Symptoms of aspiration can be asphyxia, cough, or cyanosis. Although in some cases patients may have no symptoms, an accurate and positive history even without clinical signs must be suspected doctor to a foreign body aspiration. However, in some cases, radiological intervention is normal and helps to diagnose and should be performed in all suspected cases to FBA.

FBA definite diagnosis is by bronchoscopy, and to prevent complications and possibly death, timely removing of foreign body is vital and necessary. Most of the complications of delayed diagnosis and treatment and early detection are associated with few complications. FBA potential complications include pneumomediastinum, pneumothorax, atelectasis, bronchiectasis, lung abscess, and recurrent pneumonia. Most of these complications are irreversible in people with problems diagnosed too late. Technological advances and clinical application of bronchoscopy have caused the majority of foreign bodies are removed from the respiratory system are without sequela. The removal of foreign body through undergone rigid bronchoscopy is the preferred method of treatment, but in certain cases may require surgical intervention to remove the foreign body. This report is a case of 17-month-old infant with fever, coryza, and cough symptoms with a diagnosis of pneumonia was hospitalized due to suspected pulmonary mass by chest x-ray or chest CT scan and bronchoscopy was performed and the seed was removed from the right lung.

Key Words: Child, Case report, Mass, Pulmonary foreign body.

*Please cite this article as: Sayedi SJ, Shojaeian R, Bani Hassan M, Khakshour A. A Case of Pulmonary Foreign Body Reviewed as Mass. Int J Pediatr 2016; 4(8): 2281-86.

*Corresponding Author:

Ali Khakshour, Assistant Professor, Mashhad University of Medical Sciences, Mashhad, Iran.

Email: Khakshoura@mums.ac.ir

Received date Feb10, 2016; Accepted date: Mar 22, 2016

1- INTRODUCTION

Foreign body aspiration is one of the major causes of mortality in children under 5 years old and is one of the medical emergencies. According to available statistics in the United States annually 500 to 2,000 deaths have caused by foreign body aspiration and half of these cases occurred in children under 4 years old (1). Foreign body ingestion in children is very common; causes fear and panic of parents, and due to several complications can be considered as one of the pediatric emergencies. The common maximum age is 6 months to 3 years old, but in children older than 10 years old, risk factors such as mental retardation, convulsion, and neurological disorders can also be seen and in term of gender, it is more common in males (2). The most common foreign bodies ingested by children are nuts and coins; other objects include needle, battery, and screw (3, 4). About 40% of cases, the parents are not aware of foreign body ingested by children and in many cases children are without clinical signs. Sharp foreign bodies may cause the perforation of gastrointestinal tract wall and complications. Foreign bodies that pass esophagus will pass from other parts of gastrointestinal tract (3). In cases where the foreign body stuck in the esophagus one may have symptoms such as vomiting, coughing, wheezing, drooling, neck pain, stridor and etc. In cases where the foreign body remains in the esophagus for prolonged periods may cause symptoms such as delayed growth and aspiration pneumonia. Esophageal perforation may lead to swelling in the neck, subcutaneous crepitus, and pneumomediastinum. In cases of perforation of stomach or intestines, fever, abdominal pain, and abdominal tenderness will occur (4). Typically radiography is required as the first method of investigation to determine the location of foreign body in patients suspected to foreign body ingestion. With

advances in bronchoscopy procedures, most of foreign bodies are removed without any complications by using fiberoptic endoscopy or rigid (5). The lack of detection of foreign bodies due to lack of precision in the history, incomplete clinical examination or misleading X-ray result in delayed diagnosis and increased rates of complications (6, 7). The most common complications of bronchoscopic treatment (FBA) are worsening respiratory infection, pneumothorax, pneumonia, severe bleeding, tracheobronchial tree perforation, and cardio-pulmonary arrest. Mortality rate after bronchoscopy was reported 0.8% to 1% (8).

2- CASE REPORT

Aboulfazl, 17-month-old boy infant with fever and cough and diagnosis of pneumonia was treated in a city from four last days. Cough and fever were stopped and due to turbidity in the graph (**Figure.1**) and CT scan (**Figure.2**) was suspected to lung mass and was referred to Doctor Sheikh Hospital, Mashhad- Iran. First child, NVD, term, good Apgar score, normal development, vaccination according to country protocols, no specific disease, good general condition, current weight 11.5 kg.

T = 36.8, PR = 110, RR = 28, O2S = 97%.

Lung auscultation and the rest of clinical examination were reported normal.

2-1. Initial tests

WBC = 11.7 P: 70% L: 30%
 HB = 8.8 PLt = 467000
 CRP = + ESR = 25
 BUN = 9 Cre = 0.5 Na = 140 K = 5.1
 U/A = N S/E = N.

A week later tests were checked

WBC = 9.7 P: 74% L: 24%
 HB = 10.2 PLt = 582000
 ESR = 50 CRP = 2+
 Ure = 17 Cre = 0.5 Na = 139 K = 3.9.

The right side is higher than the left side and has sonography. Supplementary CT scan of diaphragm is recommended (**Figure.2**). The initial sonography of the town: The image was not visible in favor of space-occupying lesion in the right upper and lower diaphragm. The second sonography of the town: Kanslyshn collapse of the right lower lobe and upward movement of the diaphragm were observed. There was no effusion and mediastinum was normal.

Sonography of Mashhad on 1/28/95: no finding was seen in favor of pleural

thickening, effusion or Perry Ferry soft tissue mass in the two-side thoracic cavity.

Aperture of right diaphragm was seen. Given that the symptoms were not consistent with the patient's clinical symptoms sonography was performed again and aperture was rejected and decided to do a bronchoscopy. In rigid and flexible bronchoscopy done by children's lung specialist or children's surgery sub-specialist seed was removed and in X-ray opacity was not seen (Figure 3). The patient was discharged by medical order in the next day.

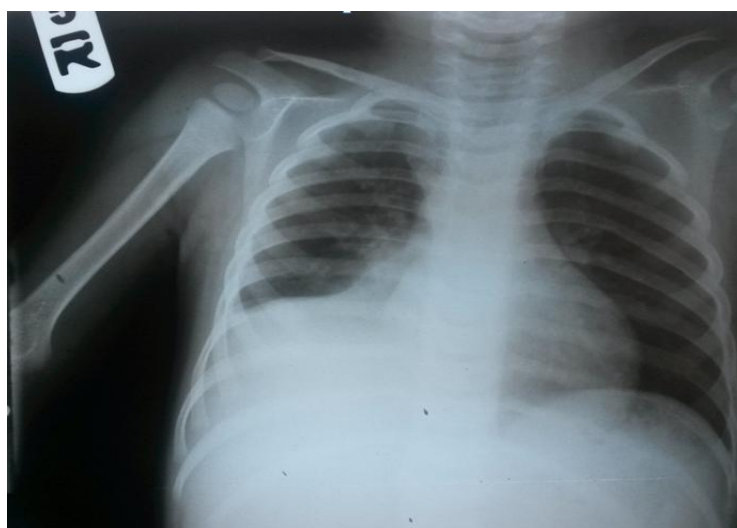


Fig.1: Before bronchoscopy

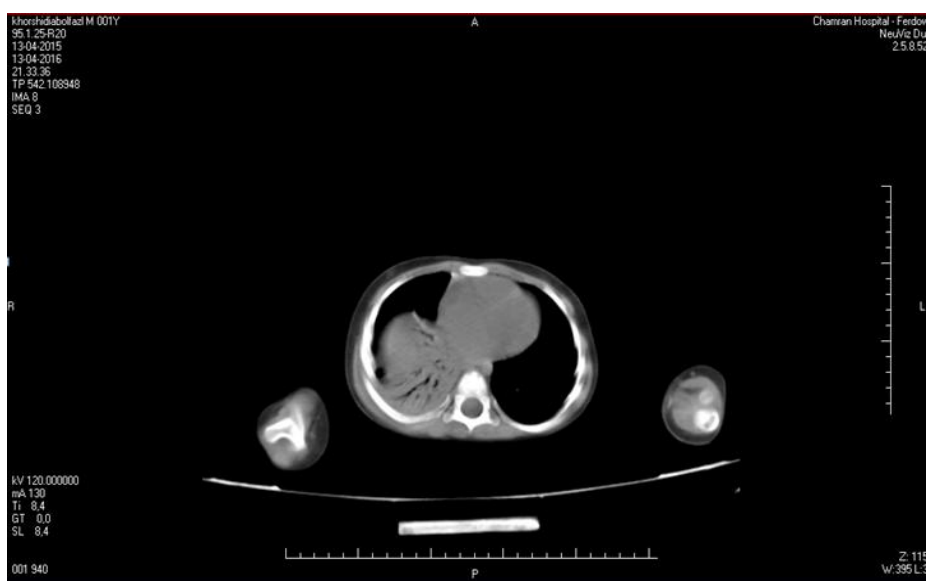


Fig.2: The CT scan done in the town

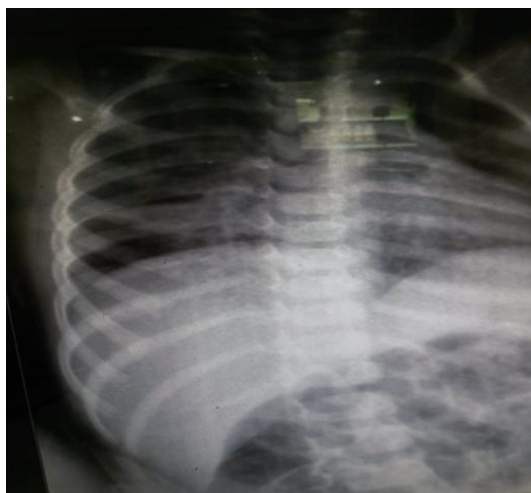

Fig. 3: After bronchoscopy and removing the FB

4- DISCUSSION

Foreign body aspiration is one of the major and threatening problems in children that despite medical advances, it is still a constant problem and a significant percentage of it occurs in children under 3 years old. Most foreign bodies of airways stick in bronchi. It's due to the size and shape of these objects that facilitate their passage through trachea and larynx. These objects often place in right main bronchus that seems it's because of the smaller concavity angle than the trachea (9). Trachea, main bronchi, and its other branches include a posterior membranous area and by horseshoe-shaped cartilages prevent airway collapse in anterior wall (10). In the study conducted on 140 patients, 55 percent of FBA cases were children under 6 years old (11). Children in this age tend to know the surrounding environment, take objects to mouth, and lack of posterior teeth development, lack of neuromuscular mechanisms of swallowing and airway protection lead to foreign body aspiration (12). In children, the most common aspirated foreign body are nuts. Adults who may consume alcohol, sedatives or head injury that all impair their judgment, Maxillo-facial trauma, neurological disorders or physical conditions such as feeling or controlling of

morsel impairment will have aspiration. Children or sick people may not be able to recall and report incident (13). Symptoms of aspiration can be asphyxia, cough, or cyanosis. Although in some cases patients may have no symptoms, depending on the position of foreign body the symptoms are different. If FB is in bronchi, symptoms will manifest in three ways: **1.** Foreign body that can only obstruct exhale causes check-valve and in this case the lung which has FB will be filled with air and mediastinum shifts to opposite side that is usually an early finding; **2.** In the ball-valve mechanism the involved lung has obstruction in breathing time and will be opened in exhalation. In this case, atelectasis will be created in the affected side and mediastina shift to the same side and this finding is usually delayed; **3.** Finally, when FB blocks the bronchi completely, stop-valve will be happened leading to consolidation of involved lobe (9). The history provided by parents of patients is usually indicative of FBA in children. Usually stating when the child was playing had severe asphyxia, bruised on his face, and his breath was cut for a short moment and after few minutes returned to normal situation. Most authors believe that history of asphyxia is the most sensitive and most specific sign of

diagnosis. However, if a child who is alone has FBA there will be no clue (11). Children or patients may not be able to recall and report incident (13).

In another study, asphyxia and shortness of breath were the most common visible signs. Viral laryngitis is common in children and imitates FBA symptoms. If a child refers with hoarseness and with or without stridor during some days, but has not the history of FBA should take proper treatment of laryngitis and asthma; and if he does not respond to treatment and has positive paraclinical symptoms diagnostic bronchoscopy should be done (11). If, FB is opaque, it will be visible in X-ray and if is bypass-valve mechanism and FB is not visible, the X-ray will be normal. Lateral decubitus chest radiography or airway fluoroscopy airway, are helpful (13). There is no difference in terms of delayed diagnosis, FB place, and radiography images in children and adults, and there is a relationship between severity of lung changes and duration of symptoms (12).

If FB remain in lung for a long time and there is worry about changes in the lung, such as abscess or bronchiectasis chest CT scan is required (11). However, in the case of chronic pulmonary and unexplained symptoms, despite a negative history and a normal chest radiography further interventions should be done to rule out FBA (12). In 45% of aspiration, laryngotracheal foreign bodies are associated with major complications and 67% are usually when diagnosis take more than 24 hours. Endoscopic technology advances and its clinical application have caused the majority of foreign bodies are removed from respiratory system without complication. Endoscopic removal of FB is the preferred method in treatment, but in certain cases may require surgical intervention to remove the FB (4, 5). Although fiberoptic bronchoscopy can be successfully used in removing FB, but in most cases especially in children in

emergencies, rigid bronchoscopy is used (13). FBA potential complications include pneumomediastinum, pneumothorax, atelectasis, bronchiectasis, recurrent pneumonia, and destruction of bronchial cartilages (14). Delay in diagnosis can lead to hypoxia, asphyxia, lung abscess, granuloma, and polyp (5). Bleeding can be caused by granulation tissue or tissue erosion in large vessels. Pneumothorax and pneumomediastinum may be due to some airway (12).

5. CONCLUSION

In patients with a positive history in favor of FBA, even without clinical symptoms and a normal chest X-ray must be doubt to foreign body except proven otherwise. Also, people who have no history of FBA, but have symptoms such as chronic cough of more than 4 weeks for which no cause has been found, prolonged pneumonia, and unresponsive to treatment with appropriate and enough antibiotics and also in patients with strong suspicion about the FBA and exist of its complications despite of negative radiographic findings, appropriate actions such as CT scan, diagnostic fiberoptic bronchoscopy, and in some cases initial rigid and diagnostic bronchoscopy should be taken, because pulmonary complications of FBA is irreversible in many cases and even may lead to death of the patient. For this reason, a diagnostic bronchoscopy in the following conditions is recommended: **1.** the children who have chronic cough lasting more than 4 weeks and in the examination for which no cause has been found; **2.** children who have frequently recurrent pneumonia and temporarily decrease the symptoms with medication; **3.** children with no history of respiratory infections who have asthma and lung collapses suddenly while playing with toys. Informing community, especially parents to the ways of prevention, symptoms, and complications of FBA has had an important role in

reducing the problem and consequently morbidity and mortality of that will be reduced as well. However, the purpose of this article was not mention and description of known complications of pulmonary foreign body, but was emphasis on how neglect to take a careful history and physical examination of a foreign body without a diagnosis, can have consequences such as bronchiectasis or other irreversible complications with many medical costs. Therefore, a careful history and appropriate physical examination are an important step in diagnosis of foreign body aspiration.

6- CONFLICT OF INTEREST

The authors had not any financial or personal relationships with other people or organizations during the study. So there was no conflict of interests in this article.

7- ABBREVIATION

NVD: Normal vaginal delivery,
T: Temperatures,
PR: Pulse rate,
RR: Respirator rate,
O2S: Oxygen saturation,
WBC: White blood cells,
P: Polymorphs,
L: Lymphocytes,
HB: Hemoglobin,
PLT: Platelets,
CRP: C-reactive protein,
ESR: Reactive sediment erythrocytes,
BUN: Blood urea nitrogen,
Cre: Creatinine,
Na: Natrium,
K: Potassium,
U/A: Urine analysis,
S/E : Stool exam,
Ure: Urea.

8- REFERENCES

1. Limper AH, Prakash UB. Tracheobronchial foreign bodies in adults. *Ann Intern Med* 1990; 112:604-9.
2. Olivers JP, Breton A, Sokhn M. Ingested foreign bodies in children: endoscopic management of 395 cases. *J Pediatr Gastroenterol Nutr.* 2000; 31(Supple 2):S1880.
3. Dahshan A. Management of ingested foreign bodies in children. *Jokia State Med Assoc* 2001; 94(6):183-6.
4. Arana A, Hauser B, Hachimi-Jdrissi A. Management of ingested foreign bodies in childhood and review of the literature. *Eur J Pediatr.* 2001; 160(8):468-72.
5. Crysedale WS, Sendi KS, Yoo Ys. Esophageal foreign bodies in children: 15 years review of 484 cases. *Ann Oto Rhinol laryngol.* 1991;100(4pt 1):320-4.
6. Al Majed SA, Ashour M, Mobeireek AF, et al. Overlooked inhaled foreign bodies: late sequelae and the likelihood of recovery. *Resp Med.* 1997; 91 (5): 293-6.
7. Baharloo F, Veyckemans F. Tracheobronchial foreign bodies: presentation and management in children and adults. *Chest* 1999; 115: 1357-62.
8. Soysal O, Kuzucu A, Ulutas H, Turkey M. Tracheobronchial foreign body aspiration. *Otolaryngol- Head and Neck Surg* 2006; 135: 223-6.
9. Cummings C. *Otolaryngology: Head and Neck Surgery.* 5th Edition. Philadelphia: Mosby: 2005. ISBN-13: 978-0323052832.
10. Way LW. *Current Surgical Diagnosis and Treatment.* Los Altos, Calif: Lange Medical Publications; 2003: 347-8. ISSN: 0894-2277.
11. Soysal O, Kuzucu A, Ulutas H, Turkey M. Tracheobronchial foreign body aspiration. *Otolaryngol- Head and Neck Surg* 2006; 135: 223-6.
12. Baharloo F, Veyckemans F. Tracheobronchial foreign bodies: presentation and management in children and adults. *Chest* 1999; 115: 1357-62
13. Yang JY, Deutsch ES, Reilly JS. Bronchoesophagology; Ballenger *Otorhinolaryngol* 2003: 1553-5. 7-Bittencourt PF, Camargos PA. Foreign body aspiration.
14. Oliveria CF, Almedia JF, Troster EJ, Vaz FA. Complications of foreign body aspiration in children; report of 5 cases and review of the literature. *Rev Hosp Clin Fac Med, Sao Paulo* 2002; 57:108-11.