

Diagnostic Value of Technetium-99m-Dimercaptosuccinic Acid Scintigraphy in Prediction of Vesicoureteral Reflux in Children with First-time Febrile Urinary Tract Infection

Fatemeh Ataei¹, Isa Neshandar Asli¹, Masoumeh Mohkam², Samaneh Hosseinzadeh³, Neamatollah Ataei^{4,5*}, Alireza Ghavi⁴, Mahmoud Yousefifard⁶, Alireza Orari⁷, Mostafa Hosseini⁸

¹Department of Nuclear Medicine, Taleghani Hospital, Shahid Beheshti University of Medical Sciences, Tehran, Iran. ²Department of Pediatric Nephrology, Pediatric Infectious Research Center, Shahid Beheshti University of Medical Sciences, Tehran, Iran. ³Department of Nuclear Medicine, Labbafinejad Hospital, Shahid Beheshti University of Medical Sciences, Tehran, Iran. ⁴Pediatric Chronic Kidney Disease Research Center, Tehran University of Medical Sciences, Tehran, Iran. ⁵Department of Pediatric Nephrology, Children's Hospital Medical Center, Tehran University of Medical Sciences, Tehran, Iran. ⁶Physiology Research Center and Department of Physiology, Faculty of Medicine, Iran University of Medical Sciences, Tehran, Iran. ⁷Department of Medicine, School of Medicine, Tehran University of Medical Sciences, Tehran, Iran. ⁸Department of Epidemiology and Biostatistics, School of Public Health, Tehran University of Medical Sciences, Tehran, Iran.

Abstract

Background: Imaging modalities such as voiding cystourethrography (VCUG), direct radionuclide cystography (DRNC), and renal cortical scintigraphy (RCS) with technetium-99m dimercaptosuccinic acid (Tc-^{99m}DMSA), are helpful in detecting possible abnormalities of urinary tract such as vesicoureteral reflux (VUR). However, there are confounding data regarding the preference of these modalities. In the present study, we aimed to assess the role of Tc-^{99m}DMSA scan in prediction of possible VUR and the subsequent need for VCUG or DRNC. **Materials and Methods:** Three hundred fifty seven children under 14 years old with first-time febrile urinary tract infection (UTI) who were admitted between April 2004 and February 2017 were enrolled. Data regarding to VCUG or DRNC in order to evaluate the presence of possible VUR were recorded. Finally, accuracy of Tc-^{99m}DMSA scans in prediction of VUR were assessed. **Results:** Analyses showed a sensitivity and specificity of 95.65% and 14.72%, respectively for Tc-^{99m}DMSA scan in detection of VUR. Patients with mild renal involvement in Tc-^{99m}DMSA scans had a 3.5-fold greater risk of having VUR than those with a normal scans (odds ratio=3.5; 95% confidence interval [CI]: 1.4-8.58; p=0.007). In addition, the risk of VUR is up to 7.0-fold greater in children with moderate renal involvement (odds ratio=7.0; 95% CI: 2.6-13.2; p<0.0001) and up to 9.2-fold greater in children with severe renal involvement (odds ratio=9.2; 95% CI: 3.2-17.3; p=0.007) in the Tc-^{99m}DMSA scans compared to those with a normal scans. **Conclusion:** According to the results, Tc-^{99m}DMSA scan can be used as a screening test in prediction of VUR in infants and children with first-time febrile UTI.

Key Words: Children, Technetium-99m dimercaptosuccinic acid Scan, Vesicoureteral reflux, Urinary tract infection.

*Please cite this article as: Ataei F, Neshandar Asli I, Mohkam M, Hosseinzadeh S, Ataei N, Ghavi A, et al. Diagnostic Value of Technetium-99m-Dimercaptosuccinic Acid Scintigraphy in Prediction of Vesicoureteral Reflux in Children with First-time Febrile Urinary Tract Infection. Int J Pediatr 2017; 5(11): 6031-40. DOI: 10.22038/ijp.2017.26012.2219

*Corresponding Author:

Neamatollah Ataei; Pediatric Chronic Kidney Disease Research Center, Tehran University of Medical Sciences, Dr. Gharib St, Azadi Avenue, 14197 Tehran, Iran. Fax: +982188989127.

Email: ataei_nm@yahoo.com

Received date: Aug.13, 2017; Accepted date: Aug.22, 2017

1- INTRODUCTION

Urinary tract infection (UTI) is one of the most common infections of childhood with an incidence of 3-7% in girls and 1-2% in boys (1, 2). Infants and children with UTI are prone to having renal parenchymal damage. Sequelae of renal injury may include hypertension, growth retardation, proteinuria and eventually, end-stage renal disease (3-9). Vesicoureteral reflux (VUR) is the most important risk factor for post-UTI renal scar formation in children. In recent years, a meaningful relation between high grade VUR and persistent renal parenchymal injury cannot be denied, despite assumptions made regarding the importance of VUR in scar formation (10-12). Although imaging modalities such as voiding cystourethrography (VCUG), direct radionuclide cystography (DRNC), and renal cortical scintigraphy (RCS) with technetium-99m dimercaptosuccinic acid (Tc-99mDMSA) are helpful in detecting possible abnormalities of urinary tract and lesions in renal parenchyma, dispute regarding indications of the mentioned modalities in children with UTI is still a hot. Among the mentioned imaging modalities, VCUG and DRNC are reliable methods for identifying VUR in children with UTI. However, both are an unpleasant invasive procedure with radiation burden that may cause dysuria, discomfort in perineum and hematuria.

In addition to mentioned side effects, the other rare complications associated with these procedures include symptomatic UTI despite prophylactic antibiotic, perforation of the bladder, sepsis, and even death (13-16). Although primary guidelines of the American Academy of Pediatrics (APP) insist on importance of cystography in diagnosis of VUR as a risk factor in children between 2 months to 2 years old with first-time febrile UTI (17), subsequent studies have questioned the importance of VUR and need for

cystography as a routine (18). In addition, recent assessment plans favor using cystography selectively in children with first-time febrile UTI. In some studies on children with first-time febrile UTI, normal Tc-^{99m}DMSA scan rarely indicated high grade VUR, so cystography were only advised in patients with RCS showing results in favor of abnormal Tc-^{99m}DMSA (12, 19). On the contrary, some researchers believe that Tc-^{99m}DMSA scan has limited ability in detection of VUR and should not be used a substitute to cystography (20, 21). However, most of these studies are conducted on children under 5 years old and strategies regarding children over 5 years old are rarely discussed (22-25). Hence, this retrospective study was conducted on children under 14 years of age with first-time UTI in order to assess the role of Tc-^{99m}DMSA scan in prediction of possible VUR and the subsequent need for VCUG or DRNC.

2- MATERIALS AND METHODS

2-1. Study design

The present retrospective diagnostic accuracy study was designed to assess the value of Tc-^{99m}DMSA scan in prediction of VUR in children with UTI admitted in two referral hospitals of Mofid and Children's Medical Center in Tehran, Iran. The present study was approved by the Ethics Committee of Tehran University of Medical Sciences. All researchers adhered to the Helsinki declaration throughout the study.

2-2. Study population

Non-randomized sampling in a consecutive manner was used in the present study. Children under 14 years old with first-time febrile UTI, with Tc-^{99m}DMSA scan, VCUG or DRNC were enrolled in the study. Children with previous history of UTI, structural abnormalities such as neurogenic bladder, posterior urethral valves, ureterocele or

other congenital anomalies were excluded from the analysis.

2-3. Data gathering

Patient profiles were screened in hospitals databases and age, gender, height, weight, date of the beginning of the UTI, admission date, interval between beginning of the infection and renal cortical scintigraphy (RCS) findings on Tc-^{99m}DMSA scan, VCUg and DRNC were recorded.

2-4. Reference test

The severity of VUR using VCUg was classified according to international reflux classification (grade I to V) (26). VUR was graded as mild, moderate, or severe by radionuclide technique (27). Demonstration of tracer reflux in only the ureter by DRNC or grade I and II VUR on VCUg was considered mild. Tracer reflux in a non-dilated renal pelvis on DRNC or grade III VUR on VCUg was graded moderate. Reflux of tracer into a grossly dilated renal pelvis on DRNC or grade IV and V reflux on VCUg was considered severe (26, 27). In cases with different severity of reflux present in each ureter, the side with the highest grade of reflux was used in classification (28). The children were divided into a low grade (normal cystography or mild VUR) and a high grade (moderate to severe VUR) group based on cystogram findings (21).

2-5. Index test

Tc-^{99m}DMSA scanning was analyzed according to the recommendations of the European Association of Nuclear Medicine Pediatric Task Group (29). A kidney uptake of 45–55% of the total renal activity was considered as normal (symmetrical renal split function). A focal reduction or absence of uptake in more than one area of the kidney was considered abnormal. Relative function of the kidney of less than 45% was also considered as

abnormal. The involvement of each kidney was visually graded as mild (focal defect in uptake), moderate (uptake of renal radionuclide of (20–40%) and severe (shrunken kidney with uptake less than 20%) (30). All children were divided into two groups according to their Tc-^{99m}DMSA findings. Based on Tc-^{99m}DMSA scan, the degree of renal parenchymal change was assessed according to patient and renal unit. The sensitivity, specificity, positive and negative predictive values and positive or negative likelihood ratios (LR) low and high-grade VUR of these methods were calculated.

2-6. Statistical analyses

Sample size was calculated using Hajian-Tilaki's method which has proposed the foundations of calculating sample size in diagnostic or prognostic accuracy studies (25). A sample size of 182 patients are needed for the present study considering a minimum Tc-^{99m}DMSA scan sensitivity of 96% in detection of VUR, 17.9% prevalence of VUR (31), a confidence interval of 95% and a marginal error of 0.1. Analyses were done using STATA 14.0. The sensitivity, specificity, positive predictive value, negative predictive value and positive and negative likelihood ratio with a confidence interval of 95 % were reported for Tc-^{99m}DMSA as a predictor of VUR. Odds ratio (OR) was calculated with a confidence interval of 95% using logistic regression in order to assess the value of Tc-^{99m}DMSA scan in identification of VUR in different grades. A p value of less than 0.05 was considered significant in all analyses.

3- RESULTS

3-1. Demographic data

In the present study, data from 357 children with a first-time febrile UTI were assessed. The age of the patients ranged from 1 month to 13 years (mean age of

3.7±3.1 years). The age distribution was as follows: 0-2 year 42.86%, 2-5 years 26.69%, 5-10 years 24.37%, and 3.08% were >10 years. Forty one boys (11.5%) and 316 girls (88.5%) were enrolled in the study. The mean interval between the diagnosis of UTI and RCS was 4.8±3.9 days (minimum of 1 day and maximum of 30 days).

3-2. Cystographic assessment

Findings was normal in 218 children (61.1%). Forty seven children (13.2%) had mild reflux, 54 (15.1%) moderate and 38 (10.6%) had severe VUR. Overall, 92 patients (25.8%) were in high grade group and 256 patients (74.2%) were in low grade group. Seven hundred fourteen renal units were present in this study. According to cystographic data, 510 (71.4%) renal units did not have VUR. Eighty seven renal units (12.2%) had mild VUR, 70 (9.8%) moderate, and 47 renal units (6.6%), had severe VUR. In other words, 116 renal units (16.2%) were in high grade group, and 598 renal units (83.8%) were in low grade group.

3-3. Tc-99m DMSA scan assessment

Of the 357 children with a first-time febrile UTI, 43 (14.0%) had normal RCS, and 314 patients (88.0%) had abnormal renal scan. The mean interval between admission and RCS was 4.8±3.9 days (minimum of 1 day and maximum of 30 days). The extent of renal involvement in Tc-^{99m}DMSA scan was mild in 214 children (59.9%), moderate in 60 (16.8%), and severe in 40 children (11.2%). One hundred eighty nine out of 714 renal units (26.5%) had normal findings in Tc-^{99m}DMSA scan, 407 renal units (57.0%) had mild involvement, 74 (10.4%) had moderate and 44 renal units (6.2%) had severe renal involvement.

3-4. Value of Tc-99m DMSA scan for detecting VUR

As shown in **Table.1**, cystography results were normal in 218 children of which 37 had normal findings on Tc-^{99m}DMSA scan. In addition, cystography results showed findings in favor of VUR in 139 children of which 133 had abnormal findings in their Tc-^{99m}DMSA scan. In other words, 88 cases were true positive, 39 true negative, 4 false negative, and 226 false positive. Analyses showed a sensitivity and specificity of 95.65%, and 14.72%, respectively for Tc-^{99m}DMSA scan in detection of VUR. The mentioned test had positive predictive value of 28.03% and negative predictive value of 90.70%. Additionally, the positive and negative likelihood ratios were 1.12% and 0.30%, respectively (**Table.2**).

3-5. Value of Tc-99mDMSA scan for detecting VUR according to renal units

Of all assessed renal units in the present study, 204 renal units had findings in favor of VUR. Assessments in 172 renal units were in favor of abnormal Tc-^{99m}DMSA scan (**Table.3**). As shown in **Table.4**, according to VUR grades in renal units, 100 renal units were true positive, 172 true negative, 17 false negative, and 425 false positive. Analyses showed a sensitivity and specificity of 85.47% and 28.81%, respectively on Tc-^{99m}DMSA for detecting the presence of VUR according to renal units. Positive and negative predictive values of the mentioned test were reported to be 19.05% and 91.0%, respectively. Additionally, positive and negative likelihood ratios of scintigraphy according to renal units were 1.20 and 0.50, respectively.

3-6. Association between the severity of renal involvement in Tc-99mDMSA scan and presence of VUR

Analyses showed that children with mild renal involvement in Tc-^{99m}DMSA scan had a 3.5-fold greater risk of having reflux than those with a normal scan (odds

ratio=3.5; 95% confidence interval [CI]: 1.4-8.58; $p=0.007$). In addition, the risk of reflux is up to 7.0-fold greater in children with moderate renal involvement (odds ratio=7.0; 95% CI: 2.6-13.2; $p<0.0001$), and up to 9.2-fold greater in children with

severe renal involvement (odds ratio=9.2; 95% CI: 3.2-17.3; $p=0.007$) in Tc-^{99m}DMSA scan compared to those with a normal scan. Therefore, the risk of VUR increases with greater renal involvement in acute Tc-^{99m}DMSA scan (**Figure.1**).

Table-1: Relation of cystography and Technetium-99m dimercaptosuccinic acid (Tc-^{99m}DMSA) scan in 357 children with a first-time febrile urinary tract infection (UTI)

Findings	Tc- ^{99m} DMSA scan	
	Normal (%)	Abnormal (%)
Normal	37 (0.17)	181 (83.0)
Mild reflux	2 (4.3)	45 (95.7)
Moderate reflux	2 (3.7)	52 (96.3)
Sever reflux	2 (5.3)	36 (94.7)

Table-2: Screening performance characteristics of Technetium-99m dimercaptosuccinic acid (Tc-^{99m}DMSA) scan in detection of vesicoureteral reflux (VUR) in 357 children with a first-time febrile urinary tract infection (UTI)

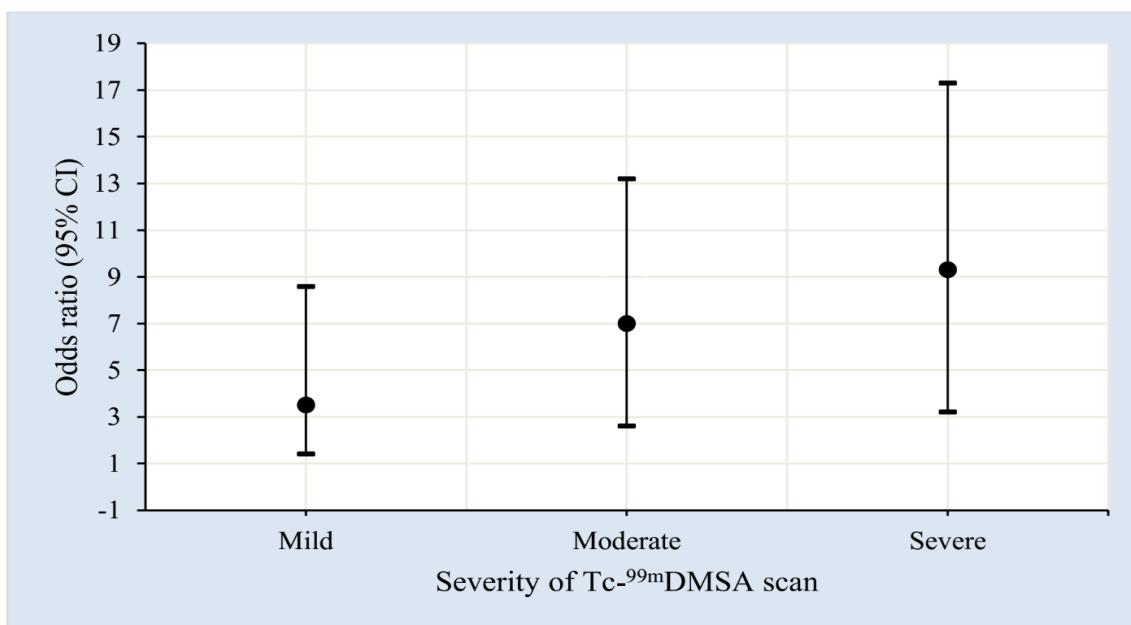
Performance	Value	95% confidence interval
True positive	88	---
True negative	39	---
False negative	4	---
False positive	226	---
Sensitivity	95.65	88.62-98.60
Specificity	14.72	10.79-19.69
Positive predictive value	28.03	23.20-33.40
Negative predictive value	90.70	76.95-96.98
Positive likelihood ratio	1.12	1.05-1.20
Negative likelihood ratio	0.30	0.11-0.80

Table-3: Relation of cystography and Technetium-99m dimercaptosuccinic acid (Tc-^{99m}DMSA) scan based on renal units

Findings	Tc- ^{99m} DMSA scan	
	Normal (%)	Abnormal (%)
Normal	157 (8.30)	353 (69.2)
Mild reflux	15 (17.2)	72 (82.8)
Moderate reflux	9 (12.9)	61 (87.1)
Sever reflux	8 (17.0)	39 (83.0)

Table-4: Screening performance characteristics of Technetium-99m dimercaptosuccinic acid (Tc-^{99m}DMSA) scan in detection of vesicoureteral reflux (VUR) according renal units

Performance	Value	95% confidence interval
True positive	100	----
True negative	172	----
False negative	17	----
False positive	425	----
Sensitivity	85.47	77.47-91.06
Specificity	28.81	25.24-32.65
Positive predictive value	19.05	15.83-22.72
Negative predictive value	91.00	85.76-94.52
Positive likelihood ratio	1.20	1.10-1.31
Negative likelihood ratio	0.50	0.32-0.79

**Fig.1:** Relationship between severity renal involvement in Technetium-99m dimercaptosuccinic acid (Tc-^{99m}DMSA) scan and odds ratio of vesicoureteral reflux (VUR); CI: confidence interval.

4- DISCUSSION

UTI is the most common bacterial infection in childhood (29, 32, 33). Its prevalence is approximately 5% in febrile infants, and 2% in febrile children under age 5 years (29, 34). In the present study, 357 infants and children between the ages of 1 month to 13 years old with first time febrile UTI were admitted and undergone systemic antibiotic therapy. Clinical features and laboratory parameters are of no help for differentiating between upper

and lower UTI in children (30, 35). Tc-^{99m}DMSA is currently considered the imaging modality of choice for estimating the presence and extension of inflammatory parenchymal changes in acute pyelonephritis (APN), and renal scarring (30, 36). Tc-^{99m}DMSA renal scanning has high sensitivity (87%), and high specificity (100%) in detecting renal parenchymal involvement in children with febrile UTI (30).

The present study showed a high frequency of acute inflammatory changes on Tc-^{99m}DMSA scan in 88% of children (73.5% of renal units). These data emphasize the fact that infants and children with first-time febrile UTI are at risk for acute inflammatory renal parenchymal damage. This result is consistent with the findings reported by others (29, 37). VUR is a known risk factor for renal scarring. In our experience, it was present in 38.9% infants and children (28.6% renal units) with first-time febrile UTI, a finding in agreement with other studies (12). Some reports have shown that increase in frequency of renal parenchymal involvement on Tc-^{99m}DMSA scan in children with febrile UTI is in association with increases in degree of VUR (38, 39).

In the present study, a significant association was found between increases in frequency of renal parenchymal involvement on Tc-^{99m}DMSA scan and increases in grades of VUR ($p=0.007$). Our findings, were concordant with results reported by some prospective studies (22, 40). In the study by Tseng et al. (37), Tc-^{99m}DMSA scan had a sensitivity and negative predictive value of 88 % in detecting high grade VUR (III-V) in cystography and a negative likelihood ratio of 0.33 was reported for Tc-^{99m}DMSA scan for ruling out VUR.

In the study by Preda et al. (27) Tc-^{99m}DMSA scan had a sensitivity and negative predictive value of 96% and 99%, respectively in detecting high grade VUR (III-V) in cystography and a negative likelihood ratio of 0.07 was reported for Tc-^{99m}DMSA scan for ruling out VUR. Similarly, in the present study, high sensitivity (95.65%), high NPV (90.70%), and low negative Likelihood ratio (0.30%) of pyelonephritis changes on Tc-^{99m}DMSA scan for detecting the presence of high-grade (III-V) VUR on VCUG or DRNC were found. It means that a normal Tc-

^{99m}DMSA renal scanning findings decreases the probability of having high-grade VUR (III-V), and this is a strong predictor of the absence of high-grade VUR in infant and children presenting with first-time febrile UTI. According to the study by Hellerstein et al. (41), antibiotic therapy can be effective in prevention of UTI in children with dilated collecting systems (grade III VUR). However, disadvantages of antibiotic therapy in children with mild VUR (grade I, II) may exceed its advantages.

In the present study, 43 out of 357 (12%) patients with febrile UTI had a normal Tc-^{99m}DMSA scan. Of the 43 patients with normal Tc-^{99m}DMSA scans, 37 (86%) did not have VUR. In assessing VUR per renal unit, 189 out of 714 (26.4%) renal units had a normal Tc-^{99m}DMSA scan. One hundred fifty seven out of 189 renal units (83.06%) with normal Tc-^{99m}DMSA did not have any findings in favor of VUR. Although the American Academy of Pediatrics (AAP) suggests performing cystography in infants and children with first-time febrile UTI for detecting of a possible VUR (42).

According to results of the present study, we do not recommend the routine performance of cystography in children with first-time febrile UTI with normal Tc-^{99m}DMSA scan. The current study revealed that Tc-^{99m}DMSA scan can be used as an appropriate screening tool instead of cystography in children with first-time febrile UTI. Acceptable sensitivity of this test confirms our findings.

4-1. Limitations of the study

One of the most important limitations of the present study is its retrospective manner. Although there was some incomplete and missing data in patient profiles, data of Tc-^{99m}DMSA and cystography scan were extracted from recorded imaging reports and were entered

in the study. Hence, the retrospective manner of the present study has not affected the main outcome of the study.

5- CONCLUSION

Infants and children with first-time febrile UTI and normal Tc-^{99m}DMSA scan, rarely have high grade VUR. High sensitivity and negative predictive value of Tc-^{99m}DMSA scan has made this modality a screening tool for detection of high grade VUR. Therefore, Tc-^{99m}DMSA scan can be used as a screening test in prediction of VUR in infants and children with first-time febrile UTI. Accordingly, VCUG or DRNC is suggested to be performed in children with an abnormal Tc-^{99m}DMSA scan.

6- CONFLICT OF INTEREST: None.

7- ACKNOWLEDGMENT

This research has been supported by Tehran University of Medical Sciences and health Services grant number: 96-01-184-34809.

8- REFERENCES

1. Winberg J, Andersen HJ, Bergström T, Jacobsson B, Larson H, Lincoln K. Epidemiology of symptomatic urinary tract infection in childhood. *Acta Paediatr.* 1974;63(s252):1-20.
2. Uhari M, Nuutinen M. Epidemiology of symptomatic infections of the urinary tract in children. *BMJ.* 1988; 297(6646):450-2.
3. Benador D, Benador N, Slosman DO, Nusslé D, Mermillod B, Girardin E. Cortical scintigraphy in the evaluation of renal parenchymal changes in children with pyelonephritis. *J Pediatr.* 1994;124(1):17-20.
4. Literature Reviews: Nephrology/Urology: Urinary Tract Infection: A Comparison of Four Methods of Investigation. *Clin Pediatr (Phila).* 1996;35(2):111-2.
5. Jacobson SH, Eklof O, Eriksson CG, Lins LE, Tidgren B, Winberg J. Development of hypertension and uraemia after pyelonephritis in childhood: 27 year follow up. *BMJ.* 1989;299(6701):703-6.
6. Ataei N, Hosseini M, Baikpour M, Ataei F, Bloori Jirandeh H, Bazargani B, et al. Etiology and outcome of chronic kidney disease in Iranian children. *Int J Pediatr.* 2016;4(7):2105-12.
7. Nakhjavan-Shahraki B, Yousefifard M, Ataei N, Baikpour M, Ataei F, Bazargani B, et al. Accuracy of cystatin C in prediction of acute kidney injury in children; serum or urine levels: which one works better? A systematic review and meta-analysis. *BMC Nephrol.* 2017;18(1):120.
8. Izadi A, Yousefifard M, Nakhjavan-Shahraki B, Baikpour M, Mirzay Razaz J, Ataei N, et al. Value of plasma/serum neutrophil gelatinase-associated lipocalin in detection of pediatric acute kidney injury; a systematic review and meta-analysis. *Int J Pediatr.* 2016;4(11):3815-36.
9. Izadi A, Yousefifard M, Nakhjavan-Shahraki B, Baikpour M, Mirzay Razaz J, Hosseini M. Diagnostic value of Urinary Neutrophil Gelatinase-Associated Lipocalin (NGAL) in detection of pediatric acute kidney injury; a systematic review and meta-analysis. *Int J Pediatr.* 2016;4(11):3875-95.
10. Winberg J. Management of primary vesico-ureteric reflux in children — Operation ineffective in preventing progressive renal damage. *Infection.* 1994; 22(S1):S4-S7.
11. Wheeler DM, Vimalachandra D, Hodson EM, Smith GH, Craig JC. Interventions for primary vesicoureteric reflux. *Cochrane Database of Systematic Reviews:* John Wiley and Sons, Ltd; 2004.
12. Hansson S, Dhamey M, Sigström O, Sixt R, Stokland E, Wennerström M, et al. Dimercapto-succinic acid scintigraphy instead of voiding cystourethrography for infants with urinary tract infection. *J Urol.* 2004;172(3):1071-4.
13. Mouriquand P. Faculty of 1000 evaluation for Does a normal DMSA obviate the performance of voiding cystourethrography in evaluation of young children after their first urinary tract infection? F1000 - Post-publication peer review of the

biomedical literature: Faculty of 1000, Ltd.; 2007.

14. Keren R. Imaging and treatment strategies for children after first urinary tract infection. *Curr Opin Pediatr.* 2007;19(6):705-10.
15. Cohen AL. Compliance With Guidelines for the Medical Care of First Urinary Tract Infections in Infants: A Population-Based Study. *Pediatrics.* 2005;115(6):1474-78.
16. Rachmiel M, Aladjem M, Starinsky R, Strauss S, Villa Y, Goldman M. Symptomatic urinary tract infections following voiding cystourethrography. *Pediatr Nephrol.* 2005;20(10):1449-52.
17. Crowley JJ, McAlister WH. Extravasation of contrast material during voiding cystourethrography. *Abdom Imaging.* 1995;20(1):68-9.
18. McAlister WH, Cacciarelli A, Shackelford GD. Complications Associated with Cystography in Children. *Radiology.* 1974;111(1):167-72.
19. Roberts KB, Downs SM, Finnell SM, Hellerstein S, Shortliffe LD, Wald ER, et al. Reaffirmation of AAP Clinical Practice Guideline: The Diagnosis and Management of the Initial Urinary Tract Infection in Febrile Infants and Young Children 2-24 Months of Age. *Pediatrics.* 2016;138(6):e20163026-e.
20. Moorthy I. The presence of vesicoureteric reflux does not identify a population at risk for renal scarring following a first urinary tract infection. *Arch Dis Child.* 2005; 90(7):733-6.
21. Majd M, Rushton HG, Jantausch B, Wiedermann BL. Relationship among vesicoureteral reflux, P-fimbriated *Escherichia coli*, and acute pyelonephritis in children with febrile urinary tract infection. *J Pediatr.* 1991;119(4):578-85.
22. Fouzas S, Krikelli E, Vassilakos P, Gkentzi D, Papanastasiou DA, Salakos C. DMSA Scan for Revealing Vesicoureteral Reflux in Young Children With Urinary Tract Infection. *Pediatrics.* 2010;126(3):e513-e9.
23. Siomou E, Giapros V, Fotopoulos A, Aasioti M, Papadopoulou F, Serbis A, et al. Implications of ^{99m}Tc-DMSA Scintigraphy Performed During Urinary Tract Infection in Neonates. *Pediatrics.* 2009;124(3):881-7.
24. Shih B-F, Tsai J-D, Tsao C-H, Huang F-Y. Reappraisal of the effectiveness of ^{99m}Tc-dimercaptosuccinic acid scans for selective voiding cystourethrography in children with a first febrile urinary tract infection. *Kaohsiung J Med Sci.* 2014;30(12):608-12.
25. Hajian-Tilaki K. Sample size estimation in diagnostic test studies of biomedical informatics. *J Biomed Inform.* 2014;48:193-204.
26. American Academy of Pediatrics. Medical versus surgical treatment of primary vesicoureteral reflux: report of the International Reflux Study Committee. *Pediatrics.* 1981;67(3):392-400.
27. Preda I, Jodal U, Sixt R, Stokland E, Hansson S. Normal Dimercaptosuccinic Acid Scintigraphy Makes Voiding Cystourethrography Unnecessary after Urinary Tract Infection. *J Pediatr.* 2007;151(6):581-4.e1.
28. Medical versus surgical treatment of primary vesicoureteral reflux: report of the International Reflux Study Committee. *Pediatrics.* 1981;67(3):392-400.
29. Hoberman A, Charron M, Hickey RW, Baskin M, Kearney DH, Wald ER. Imaging Studies after a First Febrile Urinary Tract Infection in Young Children. *N Engl J Med.* 2003;348(3):195-202.
30. Rushton HG, Majd M. Dimercaptosuccinic acid renal scintigraphy for the evaluation of pyelonephritis and scarring: a review of experimental and clinical studies. *J Urol.* 1992;148(5 Pt 2):1726-32.
31. Preda I, Jodal U, Sixt R, Stokland E, Hansson S. Normal dimercaptosuccinic acid scintigraphy makes voiding cystourethrography unnecessary after urinary tract infection. *J Pediatr.* 2007;151(6):581-4, 4.e1.
32. Marild S, Jodal U. Incidence rate of first-time symptomatic urinary tract infection in children under 6 years of age. *Acta Paediatr.* 1998;87(5):549-52.

33. O'Brien K, Stanton N, Edwards A, Hood K, Butler CC. Prevalence of urinary tract infection (UTI) in sequential acutely unwell children presenting in primary care: exploratory study. *Scand J Prim Health Care*. 2011;29(1):19-22.
34. Shaw KN, Gorelick M, McGowan KL, Yakscoe NM, Schwartz JS. Prevalence of urinary tract infection in febrile young children in the emergency department. *Pediatrics*. 1998;102(2):e16.
35. Jaksic E, Bogdanovic R, Artiko V, Saranovic DS, Petrasinovic Z, Petrovic M, et al. Diagnostic role of initial renal cortical scintigraphy in children with the first episode of acute pyelonephritis. *Ann Nucl Med*. 2011;25(1):37-43.
36. Parkhouse HF, Godley ML, Cooper J, Risdon RA, Ransley PG. Renal imaging with ^{99m}Tc-labelled DMSA in the detection of acute pyelonephritis: an experimental study in the pig. *Nucl Med Commun*. 1989;10(1):63-70.
37. Tseng M-H, Lin W-J, Lo W-T, Wang S-R, Chu M-L, Wang C-C. Does a Normal DMSA Obviate the Performance of Voiding Cystourethrography in Evaluation of Young Children after Their First Urinary Tract Infection? *J Pediatr*. 2007;150(1):96-9.
38. Lee M-D, Lin C-C, Huang F-Y, Tsai T-C, Huang C-T, Tsai J-D. Screening Young Children with a First Febrile Urinary Tract Infection for High-grade Vesicoureteral Reflux with Renal Ultrasound Scanning and Technetium-99m-labeled Dimercaptosuccinic Acid Scanning. *J Pediatr*. 2009;154(6):797-802.
39. Tsai JD, Huang CT, Lin PY, Chang JH, Lee MD, Huang FY, et al. Screening high-grade vesicoureteral reflux in young infants with a febrile urinary tract infection. *Pediatr Nephrol*. 2012;27(6):955-63.
40. Majd M, Rushton HG. Renal cortical scintigraphy in the diagnosis of acute pyelonephritis. *Semin Nucl Med*. 1992;22(2):98-111.
41. Hellerstein S. Acute urinary tract infection—evaluation and treatment. *Curr Opin Pediatr*. 2006;18(2):134-8.
42. American Academy of Pediatrics CoQI, Subcommittee on Urinary Tract Infection,. Practice Parameter: The Diagnosis, Treatment, and Evaluation of the Initial Urinary Tract Infection in Febrile Infants and Young Children. *Pediatrics*. 1999;103(4):843-52.