

Fetus in Fetus in the Sacral Sac: Report of Surgical Management Case

Halim Berdi Taneh¹, Maryam Chehrehgosha², Ghorban Mohammad Kochaki², *Soheyla Kalantari², Seyyed Nima Naleini³

¹Faculty Member of Pediatrics Surgery Department, Educational Center of Taleghani, Golestan University of Medical Sciences, Gorgan, Iran.

²Faculty Member of Surgical Technology Department, Paramedical School, Golestan University of Medical Sciences, Gorgan, Iran.

³Student Research Committee, Kurdistan University of Medical Sciences, Sanandaj, Iran.

Abstract

Background

Fetus-In-Fetu (FIF) is a rare congenital malformation, which consists of a fetus mixed with a distinct tissue that is from the other fetus of the twin. FIF is defined as a mass containing a vertebral axis that is often associated with other organs or limbs around this central axis.

Case Report

The patient was a two days old girl infant who was referred to the Taleghani Pediatric Center of Gorgan, Iran, due to a mass in sacral area measuring 8.5 x 12.5 cm with soft consistency containing a normal skin colored fluid with blood streaks and hemorrhagic and bruise colored patches since birth. The results of the mother's ultrasound in the fourth month of pregnancy had identified the cyst for the fetus. In the primary results of imaging, the first diagnosis was type 2 Sacrococcygeal teratoma (SCT). However, results of post-birth graph confirmed the presence of fetal bone structure in the infant's sacrum, so FIF was diagnosed for the infant.

Conclusion

Current imaging modalities enable accurate diagnosis before surgery. Complete resection is generally curative and allows confirmation of the diagnosis.

Key Words: Case report, Fetus-in-fetu, Sacrum, Infant.

*Please cite this article as: Berdi Taneh H, Chehrehgosha M, Kochaki GM, Kalantari S, Naleini SN. Fetus in Fetus in the Sacral Sac: Report of Surgical Management Case. Int J Pediatr 2018; 6(1): 6963-69. DOI:10.22038/ijp.2017.25826.2201

*Corresponding Author:

Soheyla Kalantari, Faculty Member of Paramedical Department, Golestan University of Medical Sciences, Gorgan, Iran.

Email: sa.kalantary@gmail.com

Received date: Nov.12, 2017; Accepted date: Dec. 12, 2017

1- INTRODUCTION

Fetus-In-Fetu (FIF) is a rare congenital malformation, which consists of a fetus mixed with a distinct tissue that is from the other fetus of the twin. Willis in 1953 defined FIF as a mass containing a vertebral axis that is often associated with other organs or limbs around this central axis. It is a rare condition featuring a monozygotic diamniotic, parasitic twin, attached by a vascular anastomosis to its host chorionic circulation, which is usually incorporated into the body of its most endoparasite twin. Its prevalence is approximately one in 500,000 live births. The mechanism of the occurrence and development of FIF has not been completely determined. In the twin egg theory is claimed that FIF is happen as a result of unequal cell division of totipotent cells from blastocysts (1, 2).

The most common place of FIF is in the behind of the peritoneum and usually occurs in the abdomen of the other fetus of the twin. But other very rare places has been reported, such as digestive tract, genitourinary system, central nervous system, pancreas, lungs, mediastinum, lymph nodes and spleen (3). Most cases of FIF present as an asymptomatic abdominal mass that is found in an infant during a scheduled physical examination (4-6).

FIF diagnosis before surgery is often possible using ultrasonography (USG), simple radiography, CT scan (CT) or magnetic resonance imaging (MRI) (7). Some researchers have shown that various organs can be seen within FIF that include limbs (82.5%), vertebral column (91%), and systems such as central nervous system (55.8%), digestive system (45%), genitourinary system (26.5%) and circulatory system (40%) (8). One of the important differential diagnosis of FIF is teratoma that several studies have brought this under discussion. The features distinguishing a FIF from a high differentiated teratoma are as follows: 1)

there must be a separate vertebral column, which demonstrates that the fetus has passed through a primary stage after gastrulation, involving formation of the neural tube, metamerisation, and symmetrical development around this axis; 2) the organs must have developed in a synchronized manner. so that all have achieved the same degree of maturation (9). Studies have shown that in these cases, if the involvement of different patient systems be low, the patient's chance of survival increases and usually final treatment is done by surgical procedure and the removal of the second embryo (4, 5). Regarding to the rare occurrence of FIF, in this study a case of two days old infant is reported with final diagnosis of FIF and its diagnostic tests in 2016.

2- CASE REPORT

The patient was a two days old girl infant who was referred to Taleghani Pediatrics Center of Gorgan, North of Iran, due to a mass in the sacral area measuring 8.5 x 12.5 cm (**Figure.1**) with soft consistency containing a normal skin colored fluid with blood streaks and hemorrhagic and bruise colored patches since birth. The results of the mother's ultrasound in the fourth month of pregnancy had identified a cyst for the fetus. The infant was born at full age weighing 4.400gr and height of 50cm in the form of cesarean section without any abnormal appearance in other parts of the body. The infant was the second child of her family and the patient's family did not mention any history of twins, multiple births or abnormal cases in previous infant.

Also, in the history that take from the mother of the patient, cerebrospinal anomalies, infant mortality, seizure, hydrocephalus or other disorders, was not reported. After birth, the infant with diagnosis of myelomeningocele was transferred to the surgery ward of Pediatric Center. In the ultrasound of the patient,

there was no sign of germinal matrix hemorrhage (GMH), intraventricular hemorrhage (IVH), intracranial hemorrhage and hydrocephalus. Also, ultrasound results showed that the intended mass was not related to the spinal canal and the vertebral column and the spinal canal was seen normally in the sacral area. Despite that, the CT- scan results confirmed the type II sacrococcygeal teratoma (SCT). However, results of post-birth graph confirmed the presence of fetal bone structure in the infant's sacrum, so

FIF was diagnosed for the infant (**Figure.2**). After the final diagnosis was performed by the pediatric surgeon, the patient was prepared for surgery under general anesthesia. The two day old infant was underwent surgery and the cyst was discarded. After transverse incision of the thick skin of the cyst, a tumor lesion with dimensions of $8 \times 6 \times 9$ cm was observed (**Figures 3, 4**). The patient was discharged 48 hours after surgery with a good general appearance. No problem was reported in the 6 month follow up of the patient.

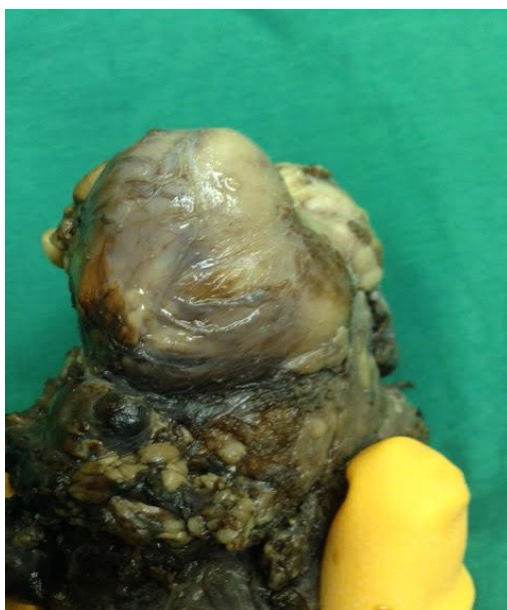

Fig.1: Sacral area mass measuring of 12.5×8.5 cm.

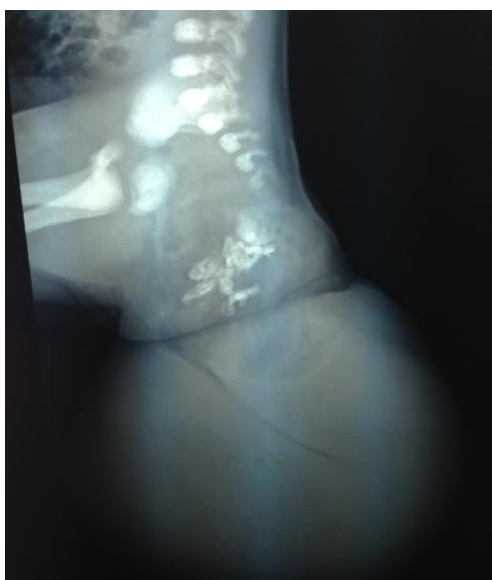

Fig.2: Post-birth graph of the Sacrum mass.

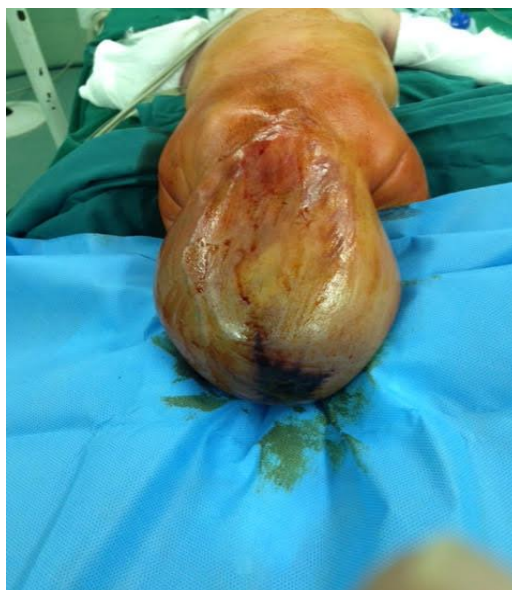

Fig.3: Tumoral lesion with dimensions of 8 x 6 x 9 cm.

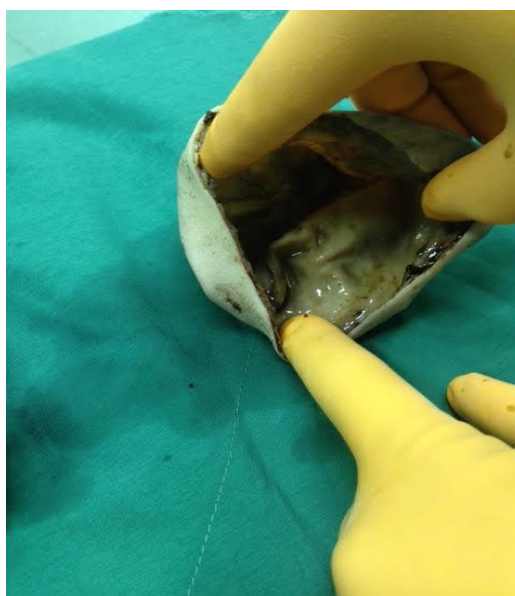


Fig.4: Transverse incision of the thick skin of the cyst.

4- DISCUSSION

Meckel was the first person who describe the term FIF in the 18th century to explain one of the fetus with a parasitic life in the other fetus of the twin, with an organ around the skeletal axis (10). In various studies, have been reported that the most place to presence of FIF is in abdominal area especially behind the peritoneum, and the most uncommon

places are in the liver, mouth, scrotum and lung parenchyma (12-14). According to Hoeffel et al. who have reviewed 87 case reports, in 80% of cases, FIF was localized in the retroperitoneal area but could also be found in atypical locations, such as skull, scrotum, mouth and adrenal glands. It was single in 88% of the cases, with different size (4 cm to 24.5 cm) and weight (1.2gr to 1.8gr). According to the presence

of organs, in 91% of cases, FIF had vertebral column, 82.5% had limbs, 55.8% had central nervous system (always anencephalic), 45% had gastrointestinal tract, 40% had vessels and 26.5% had genitourinary tract (2). But in this study, FIF has been seen in sacrum, which is a very rare case in FIF. The mass was 8.5 × 12.5 cm that is in normal range. In some studies, only in 16.7% of cases it is possible to show a preoperative diagnosis of FIF and differential diagnosis usually are teratoma and meconium pseudocyst. Teratoma is defined as a tumor containing different tissues from one or more germinal cell layers, with origin of Pluripotential cells, without systemic organization and with potential to develop into mature or malignant tissues. These tumors are typically found in the middle part of the testicles, ovaries, and sacral area (15-17).

In the primary results of imaging of the studied patient, first the diagnosis of type 2 sacrococcygeal teratoma was mentioned. In a study, differentiation between teratoma and FIF has been mentioned as in FIF, there should be a separate vertebral column and a degree of development in the organs. Spencer et al., in their study mentioned diagnostic ways for FIF, such as: 1. surrounded tissue in a separate sac, 2. natural skin, 3. separate anatomical components, and 4. having host-linked blood vessels. Consequently, according to the results of the graph of the infant's mass, the presence of vertebral column in the mass, as well as the post-surgical results of the presence of a separate sac around the mass and having diagnostic skin, this case was FIF. Also, Sathe and colleagues in their study of FIF and teratoma in 7 cases in 2014 showed that in all examined cases, due to having very few organs and vertebral column, or the spread of some organs, including the gastrointestinal tract, FIF can be differentiated from teratoma (18, 19). In

the present study, due to the large size of the mass in the patient's sacral area and the results of the follow up imaging, FIF was diagnosed at two days of infancy. Studies have shown that most of the reports that have presented in this field were during infancy (12-14) as well as various studies confirm that about 90% of FIF cases are identified before the age of 18 months, and there is no specific relationship between sex and incidence and prevalence of FIF. In addition, it should be noted that in a study, the highest age of a case that has been reported with the FIF diagnosis, was in a 47 years old man (20, 21). Imaging continues as the preferred method of diagnosis of FIF. It can easily be detected using X-ray because the presence of vertebral column in FIF is an important feature and it is a way to differentiate it from teratoma (18). In the present study, the patient's diagnosis was determined by radiography.

Treatment for fetus-in-fetu is surgical (22) to relieve obstruction, prevent further compression and possible hemorrhage, and aid diagnosis. The main indication for resection the mass is to prevent or palliate symptoms of an intraabdominal mass. The most frequent symptoms reported are distension, palpable mass, emesis, poor feeding, jaundice, and/or dyspnea (5, 23).

The excision may be associated with significant blood loss and may necessitate packing the abdomen for hemostasis. It is important to remove the total mass because the diagnosis of teratoma cannot be excluded until pathological analysis is performed. Complete removal of the mass also lowers the risk of local recurrence. Generally FIF is a benign disease but there has been one isolated case of malignancy 4months after resection of a FIF which according to that complete resection followed by postoperative surveillance of tumor markers for 2 years is recommended (24).

5- CONCLUSION

In conclusion, FIF is a rare anomaly that typically presents in infancy. Current imaging modalities enable accurate diagnosis before surgery. Complete resection is generally curative and allows confirmation of the diagnosis.

6- CONFLICT OF INTEREST: None.

7- ACKNOWLEDGMENT

Authors thanks the patient and her family and the staff of Taleghani Pediatric's Hospital of Gorgan.

8- REFERENCES

1. Ji Y, Song B, Chen S, Jiang X, Yang G, Gao X, et al. Fetus in fetu in the scrotal sac: case report and literature review. *Medicine*. 2015;94(32): e1322.
2. Brand A, Alves MC, Saraiva C, Loío P, Goulão J, Malta J, et al. Fetus in fetu—diagnostic criteria and differential diagnosis— a case report and literature review. *Journal of pediatric surgery*. 2004;39(4):616-8.
3. Gunaydin M, Celik FC, Tander B, Bozkurter AT, Sullu Y, Baris S, et al. Two cases of fetus in fetu. *Journal of pediatric surgery*. 2011;46(9):e9-e12.
4. Knox A, Webb A. The clinical features and treatment of fetus in fetu: two case reports and a review of the literature. *Journal of pediatric surgery*. 1975;10(4):483-9.
5. Eng H-L, Chuang J-H, Lee T-Y, Chen W-J. Fetus in fetu: a case report and review of the literature. *Journal of pediatric surgery*. 1989;24(3):296-9.
6. Dagradi AD, Mangiante GL, Serio GE, Musajo FG, Menestrina FV. Fetus in fetu removal in a 47-year-old man. *Surgery*. 1992;112(3):598-602.
7. Prescher LM, Butler WJ, Vachon TA, Henry MC, Latendresse T, Ignacio RC. Fetus in fetu: Review of the literature over the past 15 years. *Journal of Pediatric Surgery Case Reports*. 2015;3(12):554-62.
8. Escobar MA, Rossman JE, Caty MG. Fetus-in-fetu: report of a case and a review of the literature. *Journal of Pediatric Surgery*. 2008;43(5):943-6.
9. De Lagausie P, de Napoli Cocci S, Stempfle N, Truong Q, Vuillard E, Ferkadji L, et al. Highly differentiated teratoma and fetus-in-fetu: a single pathology? *Journal of pediatric surgery*. 1997;32(1):115-6.
10. Gangopadhyay AN, Srivastava A, Srivastava P, Gupta DK, Sharma SP, Kumar V. Twin fetus in fetu in a child: a case report and review of the literature. *Journal of medical case reports*. 2010;4(1):96.
11. Khadaroo RG, Evans MG, Honore LH, Bhargava R, Phillipos E. Fetus-in-fetu presenting as cystic meconium peritonitis: diagnosis, pathology, and surgical management. *Journal of pediatric surgery*. 2000;35(5):721-3.
12. Al-Baghdadi R. Fetus in fetu in the liver: case report and review of the literature. *Journal of pediatric surgery*. 1992;27(12):1491-2.
13. Şenyüz OF, Rizalar R, Celayir S, Öz F. Fetus in fetu or giant epignathus protruding from the mouth. *Journal of pediatric surgery*. 1992;27(12):1493-95.
14. Karaman I, Erdoğan D, Özalevli S, Karaman A, Çavuşoğlu H, Aslan MK, et al. Fetus in fetu: A report of two cases. *Journal of Indian Association of Pediatric Surgeons*. 2008;13(1):30.
15. Radvar M, Ardabili S, Norozi M, Sadeghi E. A Three-Day Old Neonate with Intrapericardial Immature Teratoma and Cardiac Tamponade. *Urmia Medical Journal*. 2014;25(2):167-71.
16. Chen CP, Chern SR, Liu FF, Jan SW, Lee HC, Sheu JC, et al. Prenatal diagnosis, pathology, and genetic study of fetus in fetu. *Prenatal diagnosis*. 1997;17(1):13-21.
17. Lee P-I, Chang M-H, Chen D-S, Lee C-Y. Serum [alpha]-Fetoprotein Levels in Normal Infants: A Reappraisal of Regression Analysis and Sex Difference. *Journal of pediatric gastroenterology and nutrition*. 1989;8(1):19-25.

18. Sathe PA, Ghodke RK, Kandalkar BM. Fetus in fetu: an institutional experience. *Pediatric and Developmental Pathology*. 2014;17(4):243-9.
19. Spencer R. Parasitic conjoined twins: external, internal (fetuses in fetu and teratomas), and detached (acardiacs). *Clinical Anatomy*. 2001;14(6):428-44.
20. Lewis R. Foetus in foetu and the retroperitoneal teratoma. *Archives of disease in childhood*. 1961;36(186):220.
21. Hoeffel CC, Nguyen KQ, Phan HT, Truong NH, Sao Nguyen T, Tran TT, et al. Fetus in fetu: a case report and literature review. *Pediatrics*. 2000;105(6):1335-44.
22. Fowler CL. Intraabdominal leg: unique variant of split notochord syndrome. *Journal of pediatric surgery*. 1998;33(3):522-4.
23. Thakral C, Maji D, Sajwani M. Fetus-in-fetu: a case report and review of the literature. *Journal of pediatric surgery*. 1998;33(9):1432-34.
24. Hopkins KL, Dickson PK, Ball TI, Ricketts RR, O'Shea PA, Abramowsky CR. Fetus-in-fetu with malignant recurrence. *Journal of pediatric surgery*. 1997;32(10):1476-9.