

Ultrasound Findings of Appendico-cecal invagination: A Case Report and Literature Review

Farhad Yousefi¹, Afruz Darvish¹, *Seyed Ali Alamdaran²

¹Resident of Radiology, Radiology Department, Faculty of Medicine, Mashhad University of Medical Sciences, Mashhad, Iran.

²Associate Professor of Radiology, Radiology Department, Faculty of Medicine, Mashhad University of Medical Sciences, Mashhad, Iran.

Abstract

Introduction

Appendicocecal intussusception is an uncommon condition which must be differentiated from other types of invagination due to different therapeutic approaches and its ultrasound findings are outspread and imperfectly presented in literature. We present a case with specific sonographic signs as well as review of related articles.

Case Presentation

A 3.5 year-old girl with intermittent crampy abdominal pain from one month ago that was recently exaggerated was associated with nausea and vomiting. She had specific sign of appendicocecal intussusception. Due to unsuccessful hydrostatic reduction, surgical intervention and appendectomy was performed.

Conclusion

The absence of clinical symptoms and ultrasound findings of small intestine obstruction and invagination target (transverse diameter less than 20 mm) adjacent to terminal ileum loop containing hypoechoic Peyer's patches can help differentiate appendicocecal invagination from the other types of invagination.

Key Words: Appendix, Child, Intussusception, Invagination, Ultrasonography.

*Please cite this article as: Yousefi F, Darvish A, Alamdaran SA. Ultrasound Findings of Appendico-cecal invagination: A Case Report and Literature Review. Int J Pediatr 2019; 7(8): 9793-98. DOI: **10.22038/ijp.2019.39478.3363**

*Corresponding Author:

Seyed Ali Alamdaran, MD, Radiology Department, Faculty of Medicine, Mashhad University of Medical Sciences, Mashhad, Iran.

Email: AlamdaranA@mums.ac.ir

Received date: Feb.15, 2019; Accepted date: Jul. 22, 2019

1- INTRODUCTION

Appendico-cecal invagination and inversion of appendix is an uncommon phenomenon denoting the advancement of appendix into lumen of cecum. The incidence rate of appendicocecal invagination among patients undergoing appendectomy has been reported to be 0.01% approximately (1). Differentiation of this type of invagination from the other types is required to avoid unnecessary invasive treatments and related complications. Although there are several papers on this type of intussusception in literature (2), few articles have considered the ultrasound findings of this disease (3-11). In this study we presented ultrasound findings of our patient and reviewed other mentioned findings of this uncommon type of intussusception in literature.

2- CASE REPORTS

A 3.5-year-old girl with alternative periumbilical colic pain during the past month was referred to Dr. Sheikh hospital (Mashhad, Iran). Fever was not detected. Exacerbation of pain, nausea and vomiting were occasionally reported recently and a tenderness in right lower quadrant (RLQ)

of the abdomen is noted. The patient underwent primary tests, which showed no positive result except for a slight increase in blood cell count with white blood cells (WBC) predominance. Complete abdominal ultrasonography was performed via Samsung WS80A machine and considering the invagination, hydrostatic reduction was done under ultrasound guidance in two consecutive days for patient, which showed recurrence and no reduction. With regard to two ultrasonographic studies and considering the remaining target appearance, entrance of normal saline into small intestine, and absence of clinical signs of obstruction, edema or ileoileal intussusception was suggested; therefore follow-up was recommended. Ultrasonography was repeated, and considering invagination appearance with a diameter of 16 mm in adjacent terminal ileum and advancement of appendix into invagination target, appendicocecal invagination was addressed (**Figure.1**). Vermiform appendix with a transverse diameter of 10 mm and thick submucosa layer was observed.

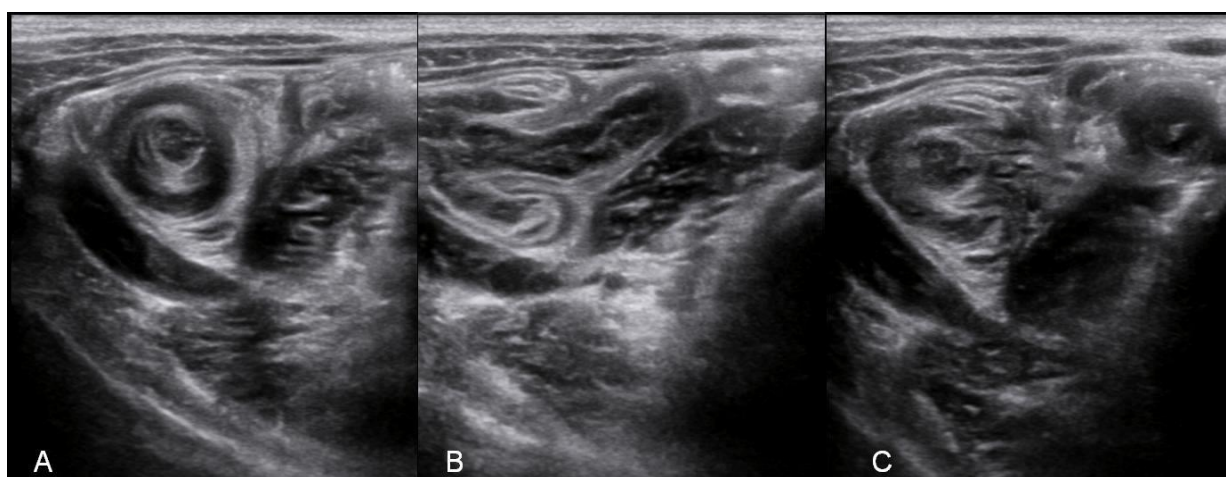


Fig.1: Ultrasound imaging of RLQ: Invagination target view in the vicinity of terminal ileum (A), adjacent terminal ileum with advancement of vermiform appendix into the cecum (B), Invagination target and target view of vermiform appendix tail with a thick layer of submucosa (C).

During surgery, invagination of base of vermiform appendix into cecum was observed (**Figure.2**). Appendectomy was done following reduction. In the pathologic examination, significant

lymphoid hyperplasia was observed in vermiform appendix. After recovering from clinical symptoms, the patient was discharged in good general condition.

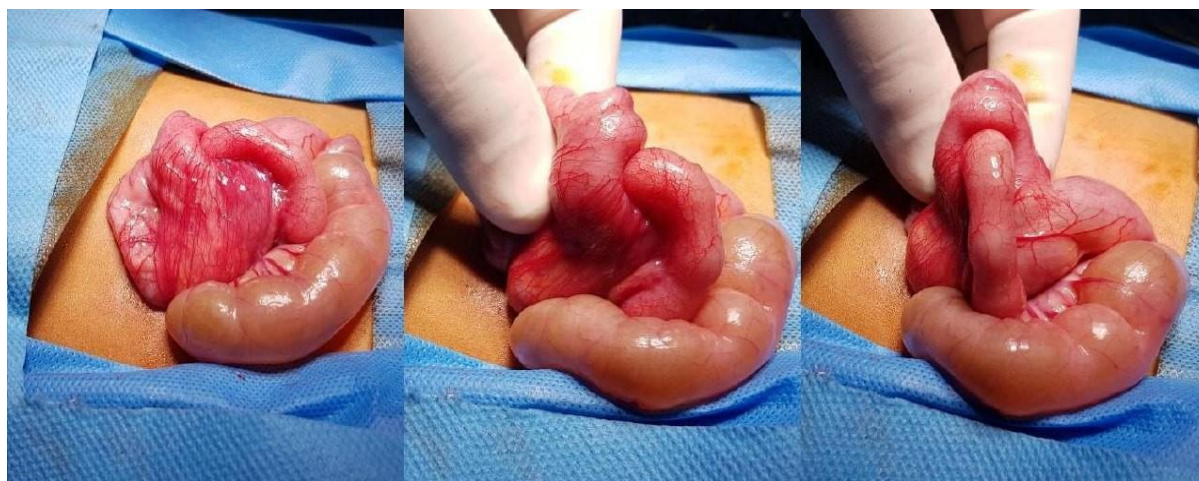

Fig.2: Surgery images shows invagination of vermiform appendix into cecum.

3- RESULTS

We reviewed all available articles which pointed to the ultrasound appearance of appendicular intussusception. Similar to all types of intussusception, ultrasound view of donut sign, target-like lesion, onion skin like lesion, multi-concentric ring, concentric layers, sonographic coiled spring sign and pseudo-kidney or RLQ position for appendicocecal invagination have been cited with different names in all papers (3-11). Detection of congested appendicitis target in RLQ is the most commonly reported sign for patients with inverted appendix (Type V) in literature (3, 5). Specific points differentiating this type of intussusception from the other types, especially ileoileal variety, which has been mentioned in a few articles, are as follows. Pumberger et al., and Maglinte et al. indicated that appendicular intussusception might show insertion of vermiform appendix into the lumen of cecum in longitudinal section in addition to multiconcentric ring in transverse sections

(8, 10). Swanger and colleagues have introduced the appearance of finger-shaped congested target with <10 mm in diameter inside the cecum implying inverted appendix (12). Alehossein et al. reported the club-shaped blind-ended intussusception to the anatomic location of the appendix vermicularis and inspection of ileocecal valve as a sign to reject ileocolic invagination as well as a specific feature of this disease (4). Koumanidou et al. also introduced two cases with small-size target containing tiny cystic lesions (appendix loop with >6 mm in diameter), suggesting intussusception with appendix lead point or Meckel diverticulum (6). Tseng et al. and Franklin et al. presented endoscopic ultrasound diagnosis of this disease with target view in the base of cecum (13, 14). In our case, in addition to 16-mm donut view in RLQ, advancement of appendix loop into intussusception was seen. Terminal ileum containing Peyer's patches adjacent to donut view also was observed separately.

4- DISCUSSION

Invagination of an intestinal loop together with its mesentery into the lumen of the same aligned intestinal loop is known as intussusception. According to its location, intussusception is divided into jejunojejunal, ileoileal, ileocolic, and colocolic types (2). If intussusception causes a pseudo-mass lesion in RLQ and the surgeon does not account intussusception in their differential diagnosis list, unnecessary invasive treatment (hemicolectomy) may ensue. The gastroenterologist may also confuse the lesion with a polyp and do biopsy, which increases the likelihood of perforation and peritonitis.

Therefore, consideration of this diagnosis by physicians as well as increasing expertise of radiologist colleagues can minimize the costs for the patient and reduce the risk of aggressive interventions as much as possible. Appendicocecal invagination or inversion of vermiform appendix is a rare occurrence. In the study of Collin et al., there was 0.01% incidence of appendicocecal invagination among 71,000 patients undergoing appendectomy (1). Mashowitz has divided appendicular intussusception into five groups: invagination of appendix tip into proximal appendix lumen, distal invagination of appendix into proximal lumen of appendix, invagination of appendix base into lumen of cecum, retrograde invagination of proximal appendix into distal appendix, and complete invagination of appendix into cecum (2, 15). Our case was the invagination of appendix base into the lumen of cecum, which is the most common type. There is possibility of involvement at any age, but most cases are observed in middle-aged women (2). Although there are several risk factors of appendicular invagination, including anatomical causes such as completely motile slender appendix with thin mesoderm as well as pathologic causes

such as endometriosis, foreign body in the appendix, fecalith, appendicitis, and appendicular masses (2, 16), endometriosis is the most common etiology in adult women (2, 17). Except for lymphoid hyperplasia, no significant finding was observed in appendicular lesion of our patient. Patients with appendicocecal intussusception may be asymptomatic, suffer acute, intermittent or chronic abdominal cramp pain, nausea and vomiting, tenderness and small mass touch in RLQ without clinical inflammatory symptoms and laboratory findings of appendicitis (2, 18, 19). In our patient, alternative recurrent pain occurred during the past month without fever and inflammation symptoms. Similar to other causes of acute abdominal pain, imaging techniques limit the differential diagnosis and lead to further attention to underlying factors of the disease. CT- scan is commonly used to examine abdominal pain. Target-like lesions and cup and ball pattern are imaging indicators of appendicocecal intussusception in CT-scan (9, 11). Colonoscopy is another diagnostic procedure for this purpose, which allows for direct observation of gastrointestinal lumen and differentiation of neoplastic processes (6).

However, ultrasound is the procedure of choice to evaluate intussusception in pediatric patients. In all kinds of intussusception, sonographic donut sign, target-like lesion, onion skin-like lesion, multi-concentric ring, concentric layers, sonographic coiled spring sign, pseudo-kidney, or RLQ mass is seen, a sign expressed for appendicular invagination in all related papers with different names (3-11). The transverse diameter of the donut due to ileocolic and cecocolic invaginations is usually >20 mm, while the diameters of transient enteroenteric and appendicocecal invaginations are >20 mm and complete inverted appendix diameter is >10 mm (2,

7, 20). Visualization of appendicitis target in RLQ is the most common view reported for patients with inverted appendix (Type V) in literature (3, 5). In addition, inverted appendix can be a lead point for ileocolic or cecocolic invaginations (7, 21). Therefore, appendicular intussusception can mimic all types of invagination, including ileoileal (due to diameter of >20 mm), ileocolic and cecocolic invaginations (due to the lead point generation for this type of invagination), invaginations with Meckel diverticulum or appendix masses and even vermicular appendix lead point (complete inverted appendix), this lead point should be considered in all types of invagination (2, 7, 21). Anyway, the specific points distinguishing this type of intussusception from the other types (especially ileoileal type) have been mentioned in a few papers as follows:

1. Multiconcentric ring with insertion of appendix into the lumen of cecum in the study of Pumberger et al. (10).
2. View of congested finger-shaped target with a diameter of <10 mm within the cecum denoting inverted appendicitis in Swanger's research (12).
3. The club-shaped blind-ended intussusception to anatomic location of appendix vermicularis in Alehossein et al.'s study (4).
4. Tseng et al. mentioned endoscopic ultrasound diagnosis with visualization of multicentric view at the base of cecum (14).
5. Visualization of a small cystic lesion (appendicular loop with >6 mm diameter) in target view suggesting intussusception with appendix lead point or Meckel diverticulum in Koumanidou et al.'s study (7).

In our patient, specific diagnosis of appendicocecal invagination was suggested by three signs: diameter of <20 mm (16 mm) in RLQ, extension of

appendix loop into the donut and visualization of terminal ileum containing separate Peyer's patches adjacent to donut view. Observation of terminal ileum and ileocecal valves separately, has also been noted for rejection of ileocolic invagination in Alehossein et al.'s research (4). Overall, although it is not possible to differentiate ileocolic and cecocolic intussusceptions, with appendix lead point from Meckel's diverticulum lead point, with the help of ultrasound and considering the difficulty of differentiating appendicocecal invaginations from ileoileal invagination considering >20 mm in diameter of all of them, attention to specific differential findings such as extension of appendix into lumen of cecum or into intussusception donut as well as identification of natural terminal ileum in its adjacent target are good diagnostic findings.

5- CONCLUSION

The absence of clinical symptoms and ultrasound findings of small intestine obstruction and adjacent invagination target (diameters of < 20 mm) to terminal ileum loop containing hypoechoic Peyer's patches can help differentiate appendicular invagination from the other types of invagination.

6- AUTHORS' CONTRIBUTION

Study concept and design: third author. Analysis and interpretation of data: first and third authors. Drafting of the manuscript: first and second authors. Critical revision of the manuscript for important intellectual content: first and third authors.

7- CONFLICT OF INTEREST: None.

8- REFERENCES

1. Collins D. 71,000 human appendix specimens-A final report, summarizing forty years study. *Am j proctol.* 1963;14:365-81.

2. Wexelman B. Intussusception of the Appendix: New trends and comprehensive analysis of 140 case reports. 2009.
3. Alaei A. Reducible appendiceal intussusception: a case report and review the literatures. *J Pediatr Rev.* 2013;1:70-6.
4. Alehossein M, Alizadeh H, Nahvi H, Ghasemi Esfe AR, Vaziri Bozorg SM. Preoperative sonographic diagnosis of appendiceal intussusception: a case report. *Journal of Clinical Ultrasound.* 2009;37(6):363-5.
5. da Silva MRC, Pinus J, Ganc AJ, Falleiros G, Garcia RG, Pinus J, et al. Intussusception of cecal appendix. *Einstein.* 2008;6:206-8.
6. Holt S, Samuel E. Multiple concentric ring sign in the ultrasonographic diagnosis of intussusception. *Gastrointestinal radiology.* 1978;3(1):307-9.
7. Koumanidou C, Vakaki M, Theofanopoulou M, Nikas J, Pitsoulakis G, Kakavakis K. Appendiceal and appendiceal-ileocolic intussusception: sonographic and radiographic evaluation. *Pediatric radiology.* 2001;31(3):180-3.
8. Maglinte DD, Fleischer AC, Chua GT, Kelvin FM. Sonography of appendiceal intussusception. *Gastrointestinal radiology.* 1987;12(1):163-5.
9. Pickhardt PJ, Levy AD, Rohrmann Jr CA, Kende AI. Primary neoplasms of the appendix: radiologic spectrum of disease with pathologic correlation. *Radiographics.* 2003;23(3):645-62.
10. Pumberger W, Hörmann M, Pomberger G, Hallwirth U. Sonographic diagnosis of intussusception of the appendix vermiformis. *Journal of clinical ultrasound.* 2000;28(9):492-6.
11. Siddiqi AJ, Arafat O, Nikolaidis P, Yaghmai V. MDCT diagnosis of ileocolic intussusception secondary to an appendiceal mucocele: value of multiplanar reformation. *Emergency radiology.* 2007;13(5):273-5.
12. Swanger R, Davis S, McBride W, Rachlin S, Sonke P-Y, Brudnicki A. Multimodality imaging of an appendiceal intussusception. *PediatricRadiology.* 2007;37(9):929-32.
13. Franklin A, Coles C, Changoor N, Gonzalez T, Cornwell III E, Burch-Smith R, et al. Appendiceal mucinous neoplasm. *CRSLS* e2014.16.
14. Tseng PH, Lee YC, Chiu HM, Wu MS, Lin JT, Wang HP. Appendiceal intussusception diagnosed with endoscopic sonography. *Journal of Clinical Ultrasound.* 2006;34(7):348-51.
15. Mcswain B. Intussusception of the appendix: review of the literature and report of a case. *South Med J.* 1941;34:263-71.
16. Katara AN, Rathod M, Bhandarwar AH, Singhal T. Inversion of Appendix with Appendiculo-Caeco-Colic Intussusception. 2002.
17. Iqbal CW, Kamath AS, Zietlow SP. Appendiceal intussusception masquerading as an ileocolic intussusception. *Journal of Gastrointestinal Surgery.* 2012;16(5):1076-77.
18. Kim YH, Blake MA, Harisinghani MG, Archer-Arroyo K, Hahn PF, Pitman MB, et al. Adult intestinal intussusception: CT appearances and identification of a causative lead point. *Radiographics.* 2006;26(3):733-44.
19. Komine N, Yasunaga C, Nakamoto M, Shima I, Iso Y, Takeda Y, et al. Intussusception of the appendix that reduced spontaneously during follow-up in a patient on hemodialysis therapy. *Internal medicine.* 2004;43(6):479-83.
20. Liubashevsky N, Hiller N, Rozovsky K, Segev L, Simanovsky N. Ileocolic versus small-bowel intussusception in children: can US enable reliable differentiation? *Radiology.* 2013;269(1):266-71.
21. Coulier B, Pestieau S, Hamels J, Lefebvre Y. US and CT diagnosis of complete cecocolic intussusception caused by an appendiceal mucocele. *European radiology.* 2002;12(2):324-8.