

Traumatic Habit Causing Gingival Recession in a Child: 3-Year Follow Up

*Adilis Kalina Alexandria¹, Ticiana Medeiros de Sabóia¹, Erika Calvano KÜchler²,
Marcelo de Castro Costa¹

¹ Department of Pediatric Dentistry and Orthodontics, Faculty of Dentistry, Federal University of Rio de Janeiro, Rio de Janeiro, RJ, Brazil.

² Unit of Clinical Research, Fluminense Federal University, Niterói, RJ, Brazil.

Short title: Gingival Recession Treatment: 3Year Follow Up

Abstract

Introduction

The purpose of this report was to present a successful treatment approach in an unusual gingival recession as a result of finger sucking traumatic habit associated with high labial frenum.

Case Report

A 10-year-old girl presented moderate pain, recession in the mandibular right incisor and finger sucking habit. The performed treatment was: oral hygiene instruction, use of palatal appliance, psychological support and frenectomy. After three years follow up, significant increases in the width of keratinized gingival, root coverage and profits in clinical attachment levels were observed. Conclusion: This case report showed great results in recovery of the periodontal health in a child.

Key Words: Gingival recession, Habits, Labial frenum.

Corresponding Author:

Adilis Kalina Alexandria, MD, Disciplina de Odontopediatria da Faculdade de Odontologia – Universidade Federal do Rio de Janeiro, Caixa Postal: 68066, Cidade Universitária – CCS, CEP: 21941-971, Rio de Janeiro – RJ, Brazil.

Email: adilis.alexandria@gmail.com

Received date: Jan 14, 2015 ; Accepted date: Jan 22, 2015

Introduction

Gingival recession (GR) can be defined as the displacement of the gingival margin apically from the Cementoenamel Junction (CEJ). GR can be localized or generalized, and be associated with one or more surfaces (1, 2). The resulting root exposure is not aesthetically pleasing and may lead to sensitivity (2).

This is an intriguing condition that can be influenced of several factors in its etiology: anatomical, physiological, pathological and traumatic, not necessarily acting synchronously (3, 4). The occurrence of GR at a given site may be difficult to explain fully, and any subsequent changes may be hard to predict (1).

Mechanical trauma like finger sucking habit and accumulation of biofilm have been described how main etiological condition in the occurrence of recession (5). High frenum attachment has been considered a risk factor, and when is present, increases the inflammatory disease (3, 6).

Both may cause GR due to pressure on gingiva and, in these cases, nonsurgical strategies are the first choice for the treatment (1, 3, 7). However, when high frenum insertion have caused an inadequate width of keratinized tissues, pressure on the marginal tissues and is associated with inflammatory condition the frenectomy is recommended (8). This report presents a successful treatment approach of an unusual gingival recession as a result of finger sucking traumatic habit associated with high frenum in a child.

Case Presentation

A 10-year-old girl was referred to the Pediatric Dental Clinic at the Federal University of Rio de Janeiro, Brazil, for dental treatment with complain of gingival recession

associated with the mandibular right incisor. Upon questioning the patient, she and her mother admitted that she has been finger sucking habit for a long period of time.

The patient related history of pain and sensitivity in this area. The patient's medical history was non-contributory and she did not take any medications. Clinical evaluation revealed gingival recession on the buccal surface extending 3 mm apical to the CEJ and a narrow zone of attached gingiva measuring approximately 1 mm. There wasn't loss of papilla but there was moderate gingival overgrowth on the distal aspect of the incisor. The gingiva in these regions had edematous, reddish and ulcerated appearance. Plaque deposits were minimal. The patient also had high frenum insertion, when the lip was distended could see a moderate tension (Figure.1a).

Written informed consent was obtained from the patient's parent after all treatment procedures had been fully explained.

The treatment required discovery and elimination of the intrinsic emotional factors and extrinsic contributing factors. Therefore, was choose how treatment an association of palatal appliance to remove the habit with surgical frenum removal, before surgical treatment, the patient underwent professional teeth cleaning, oral hygiene instruction, and psychological support to help in the elimination of oral habit.

Thus, was confectioned a removable appliance with palatal grade to control the sucking habit (Figure.1b), the patient and her parents received instructions about the appliance and the need of constantly use. Associated to elimination of the habit was made a surgical removal of the high frenum insertion. In the frenectomy a local anesthetic was administered and an incision on the frenum was made at the level to the inserted gingival, after the cut was sutured with 4-0 silk suture.

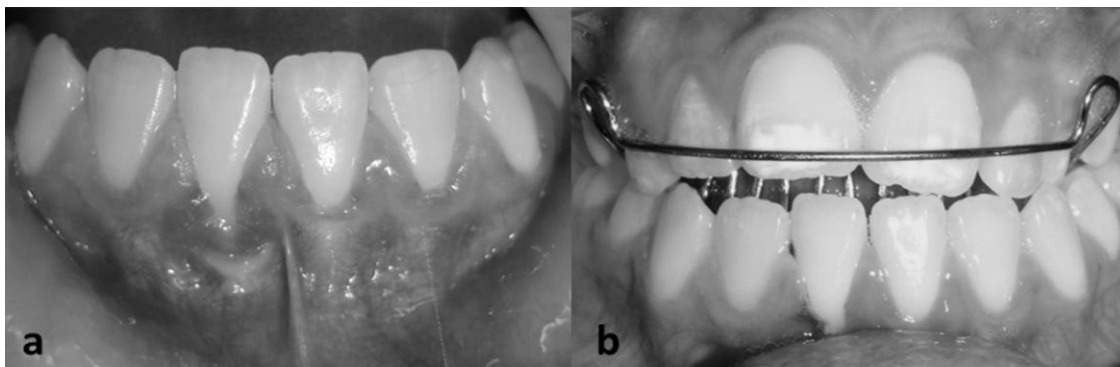


Fig.1: a- Gingival recession on the buccal surface associated with the mandibular right incisor, edematous, reddish, ulcerated appearance and high frenum insertion with big tension when the lip was distended. b- Removable appliance with palatal grade to control the sucking habit.

After the surgical was prescribed analgesics, were given home care instructions and instructed to rinse once a day with 0.12% chlorhexidine rinse for one week, the sutures were removed seven days after surgery, professional prophylaxis was done monthly to the firstly six months and then at 3-month interval. After six months the palatal appliance was removed because the finger sucking habit

was discontinued. Six months postoperatively, normal appearance was established and the amount of attached gingiva was approximately 3 mm (Figure.2a). After three years late surgical procedure, free gingival margin was located less than 0.5 mm apically to the CEJ and the gingival margin is in harmony with the neighboring teeth and the patient are in follow until now (Figure. 2b).

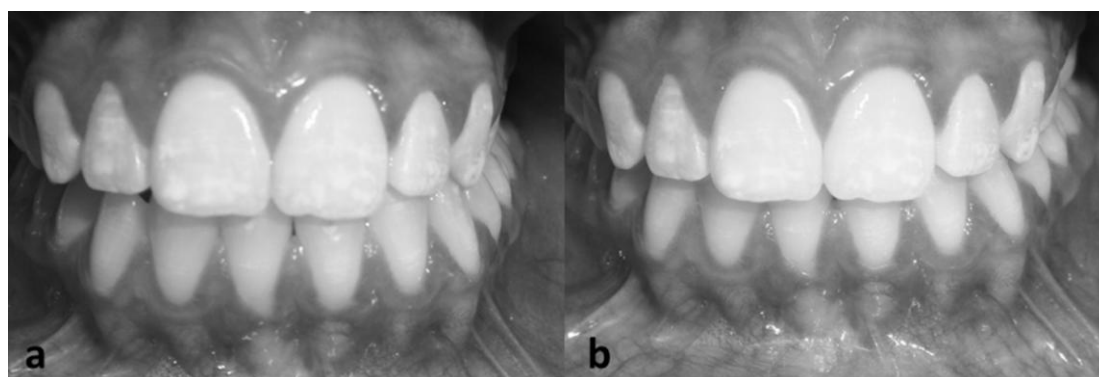


Fig. 2: a- Normal appearance and the amount of attached gingiva was approximately 3 mm six months postoperatively. b- Gingival margin in harmony after three years late surgical procedure.

Discussion

The mechanism by which GR occurs is not well understood but inflammatory nature is the most accept to explain (1, 2). Inflammatory periodontal diseases have as the main etiological factors: accumulation of dental biofilm and mechanical trauma (2). Several other risk factors have been postulated to play a role in the occurrence of recession, including alveolar bone dehiscence, high frenum attachment, and smoking (6).

In the present case, the mechanical trauma associated with high frenum insertion was considered the GR etiologic factor, causing attachment loss, edema, pain, tooth sensibility and ulceration. This case demonstrates the importance of history of the patient linked with complete anamnesis to obtain essential information relative to etiology.

Self-inflicted gingival injuries in children and adolescents can occur as a result of accidental trauma, premeditated infliction, or chronic habits such as fingernail biting, digit sucking,

or sucking on objects such as pens or pencils (4, 7).

Finger sucking habit can promote changes in dental, gingival, bone, and muscle tissues, their development being determined by intensity, frequency and duration of inappropriate pressure (5). This habit normally causes a strain, physical trauma in the marginal gingiva and occlusal abnormal forces in gingival tissue (4, 9). It's have been associated with the beginning and progression of gingival recession (9). In the present case, the mechanical trauma contributed to gingival recession and the palatal appliance was essential for the removal of the habit.

Emotional disorder is an etiology to self-inflicted oral injuries (3). In the present case, the patient was anxious and this situation contributed to maintenance the finger sucking habit, it's was initiated in early childhood. In these cases, are important besides oral strategies to discontinue the habit, psychological support as was done in this case report. High frenum is one of the most risk factors of GR, after only smoking and traumatic tooth-brushing (3, 7). When an inadequate width of keratinized tissues is associated with imflammatory and compromise the patient's ability to control biofilm the frenectomy is recommended (8). In the case presented here, treatment of the gingival recession was done surgical periodontal treatment to auxiliary in the gingival recovery after discontinued the finger sucking habit. Frenectomy have been utilized to increase amounts of keratinized tissue and obtain root coverage, in cases with small gingival recession (8, 10). Therefore, the frenectomy was considered necessary to improve marginal adaptation and to inhibit further apically-directed loss of soft tissues and bone.

Conclusion

In this case report was showed that it is possible treat gingival recession and recovery the periodontal health of a child patient with a sucking habit associated with high frenum insertion. Frenectomy and the palatal appliance were used to remove the etiological factors, and psychological support was an important tool to stabilize the periodontal condition it helped to control the habit.

Regular monitoring, supervision with tooth-brushing and dental biofilm control are essential for the maintenance of periodontal health of pediatric patients. Dentists should be aware that the habit of sucking is very common among children and can cause gingival recession due to occlusal trauma generated by the finger, it is important that the dentist be alert to act early and properly.

Conflict of interests: None

References

1. Smith RG. Gingival recession. Reappraisal of an enigmatic condition and a new index for monitoring. *Journal of clinical periodontology* 1997; 24(3):201-5.
2. Kassab MM, Badawi H, Dentino AR. Treatment of gingival recession. *Dental clinics of North America* 2010; 54(1):129-40.
3. Susin C, Haas AN, Oppermann RV, Haugejorden O, Albandar JM. Gingival recession: epidemiology and risk indicators in a representative urban Brazilian population. *Journal of periodontology* 2004;75(10):1377-86.
4. Tugnait A, Clerehugh V. Gingival recession-its significance and management. *Journal of dentistry* 2001; 29(6):381-94.
5. Bishara SE, Larsson E. Finger habits: their effects and their treatments-part 1. *Dent Assist* 2007; 76(1):14-18.
6. Joshipura KJ, Kent RL, DePaola PF. Gingival recession: intra-oral distribution and associated factors. *Journal of periodontology* 1994; 65(9):864-71.
7. Toker H, Ozdemir H. Gingival recession: epidemiology and risk indicators in a university dental hospital in Turkey. *International journal of dental hygiene* 2009; 7(2):115-20.
8. Minsk L. The frenectomy as an adjunct to periodontal treatment. *Compend Contin Educ Dent* 2002; 23(5):424-28.
9. Krejci CB. Self-inflicted gingival injury due to habitual fingernail biting. *Journal of periodontology* 2000; 71(6):1029-31.
10. Mello-Moura AC, Cadioli IC, Correa MS, Rodrigues CR, De Nardi Fonoff R. Early diagnosis and surgical treatment of the lower labial frenum in infancy: a case report. *The Journal of clinical pediatric dentistry* 2008; 32(3):181-83.