

Comparison of Fetal Echocardiography for Fetal Cardiac Structure in Women with Gestational Diabetes Mellitus and Normal Pregnancies

Hadi Teimouri¹, *Mohammad Ghasem Hanafi¹, Mohammad Momen Gharibvand¹

¹Department of Radiology, Faculty of Medicine, Ahvaz Jundishapur University of Medical Sciences, Ahvaz, Iran.

Abstract

Background

Increased metabolic rate of hyperglycemia in gestational diabetes causes macrosomia, which can also affect the fetal heart. The thickness of the walls of the heart and its function in women with gestational diabetes mellitus (GDM) can change over time before treatment. We aimed to evaluate fetal cardiac structure in terms of ventricular wall thickness and its function in women with GDM and normal pregnancy for indirect evaluation of the effects of hyperglycemia on the heart.

Materials and Methods

In this case-control study, pregnant women who referred to Imam Khomeini hospital, Ahvaz, Iran that had normal ultrasound anomaly scan between the ages of 18 to 22 weeks; in 26-28 weeks of pregnancy using 3-hour glucose tolerance test, based on the results were divided into two groups of gestational diabetes (cases, n=45), and normal (control, n=48 group). Fetal echocardiography was performed between the ages of 28 to 32 weeks and the thickness of the ventricular and inter-ventricular septum and the shortening fraction were compared.

Results

Ninety-three pregnant women were participants. The mean age of the subjects was 26.33 ± 4.88 years. There was a significant and direct relationship between right ventricular wall thickness, left ventricular thickness and intra ventricular septum, besides, right ventricular fractional shortening increased significantly in the diabetes group compared to the normal pregnancy group ($P < 0.05$); however, there was no significant difference in left ventricular function between the two groups.

Conclusion

Based on the results, significant increases in the right ventricular wall thickness, left ventricular thickness and intra ventricular septum, as well as right ventricular fractional shortening; which points to the importance of fetal echocardiography in GDM.

Key Words: Fetal echocardiography, Gestational diabetes, Pregnant women.

*Please cite this article as Teimouri H, Hanafi MG, Momen Gharibvand M. Comparison of Fetal Echocardiography for Fetal Cardiac Structure in Women with Gestational Diabetes Mellitus and Normal Pregnancies. Int J Pediatr 2020; 8(3): 11035-40. DOI: [10.22038/ijp.2020.47169.3824](https://doi.org/10.22038/ijp.2020.47169.3824)

*Corresponding Author:

Mohammad Ghasem Hanafi, MD, Department of Radiology, Faculty of Medicine, Ahvaz Jundishapur University of Medical Sciences, Ahvaz, Iran. Address: Golestan Blvd., P.C. Box# 6135733119, Ahvaz, Iran.

Email: gaseghanafi@gmail.com

Received date: Aug.23, 2019; Accepted date: Jan. 22, 2020

1- INTRODUCTION

The progression of maternal hyperglycemia is one of the risk factors for the embryo during pregnancy, and Gestational diabetes mellitus has an estimated prevalence of 2-5% (1), which has been rising in recent years. Gestational diabetes mellitus is associated with higher mortality and morbidity rates (2, 3). Hypertrophic cardiomyopathy of the embryo has been reported in up to 40% of diabetic mothers and 5% of them are symptomatic (3-5). Although many fetal cardiomyopathies are transient with diabetic mother, and there are some important complications on cardiac performance and structure (6, 7), gestational diabetes mellitus can lead to abortion or malformation in early pregnancy. However, more than 28 weeks can also cause anomalies in the fetus, the most common finding being macrosomia and respiratory distress. The effect of hyperglycemia on the heart of the fetus can be diastolic function and fetal myocardial hypertrophy (8-11).

An increase in the thickness of the ventricle wall in embryos of diabetic mothers has been shown to be due to hypoxia or unknown factors (12). Some studies have shown that hypertrophic cardiomyopathy (HCM) changes occur before intracardiac blood flow changes (13), and other studies suggest hypertrophic cardiomyopathy in relation to changes in cardiac blood flow (14-16). However, no accurate study has been done to assess and diagnose hyperglycemia in mothers of gestational diabetes on the structure and function of the heart in early detection of changes. Therefore, the purpose of this study was to determine the diagnosis of newly diagnosed gestational diabetes mellitus and to compare the normal group for embryo echocardiography between the gestational age of 28-32 weeks in terms of ventricular

wall thickness, right and left ventricular wall thickness, and the comparison of shortening right and left ventricular fraction.

2- MATERIALS AND METHODS

2-1. Study design

In this case-control descriptive-analytic study, pregnant women with gestational age between 28-32 weeks who referred to Imam Khomeini Ultrasound Center, Ahvaz, Iran in 2018-19 were selected. After visit of obstetric and gynecologist at the time of the screening of the glucose tolerance test of the abnormal criteria and defined as gestational diabetes mellitus as the case group (n=45), and the subjects without the findings of abnormal were identified in the oral glucose tolerance test (OGTT) as a control group (n=48). In addition, mothers with a history of diabetes mellitus type 1 or 2 or fetal congenital heart disease, non-cardiac, intrauterine growth restriction, oligohydramnios or polyhydramnios or pathologic findings in screening of the first trimester for nuchal translucency were excluded from the study.

Biometric and fetal echocardiography were evaluated using a GE Ultrasound Machine (GE Vuluson E6), and a transducer (3.5–5MHz). Biometric measurements were performed using four parameters of head circumference, abdominal circumference, biparietal diameter, and femur length. In addition, the fetus was subjected to cardiac size and function echocardiography that the size of the heart in the end-diastolic state, such that the apex is at 3 or 9 (to prevent a bony shadow on the heart), and the heart in the four-chamber view, and not more than one gear in the field, were measured at the level below the hinge using m -mode. An appropriate guide for determining the thickness of the heart shows in **Figure.1**.

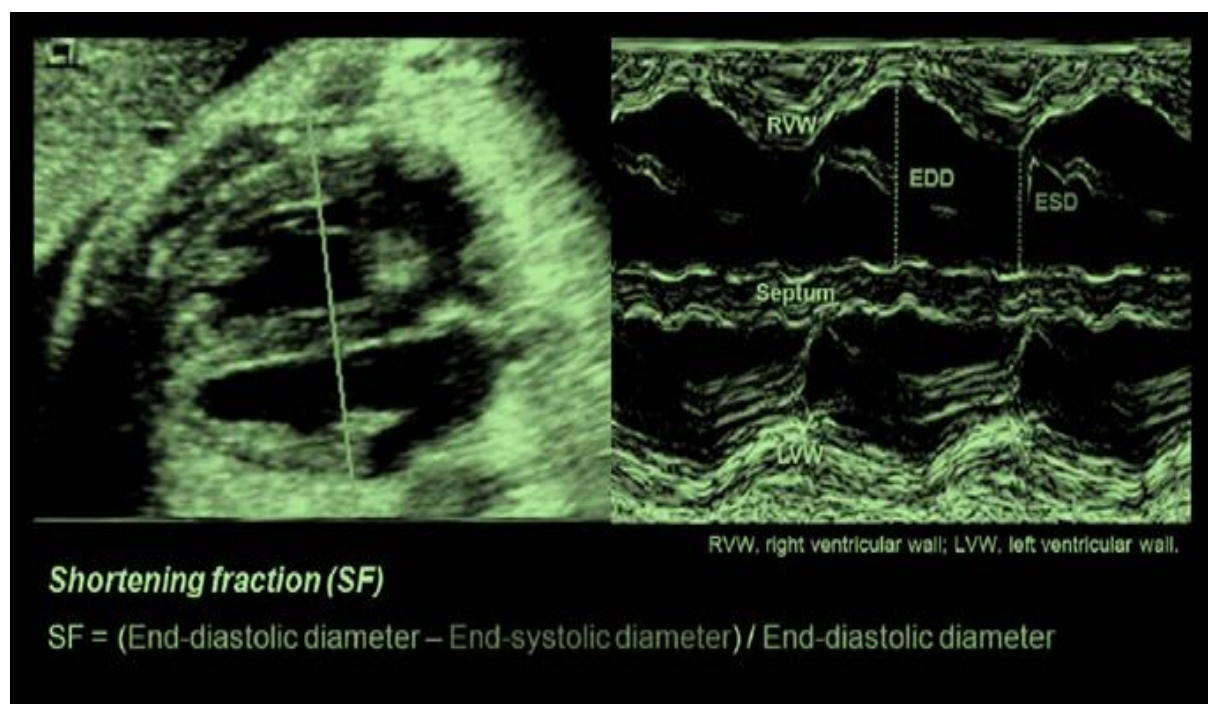


Fig.1: The 4-chamber transverse view and the use of m-mode for functional and thickness evaluation of the fetal heart.

2-2. Ethical consideration

The present study was approved by the Ethics Committee of Ahvaz Jundishapur University (ID-code: IR.AJUMS.REC.1398.309).

2-3. Statistical analysis

Continuous variables were compared by t test or one-way analysis of variance with Bonferroni correction, and correlations were calculated by the Pearson coefficient. $P < 0.05$ was considered significant. SPSS software version 22.0 for Windows (IBM Corporation, Armonk, NY) was used to perform statistical analysis. Linear regression was used to control the effects of confounders.

3- RESULTS

This study was performed to compare fetal echocardiographic findings in diabetic and healthy pregnant women

including 93 pregnant women between the ages of 19-40 years with mean age of 26.33 years and standard deviation of 4.88. About 76.3% were younger than 30 years and 23.7% were older than 30 years. Forty-five patients (48.3%) were the diabetic mothers, and 48 (51.6%) were healthy pregnant mothers. The minimum gestational age was 19 years, and the highest was 40 weeks. The mean gestational age in the case and control groups was 29.80 ± 1.52 and 29.56 ± 1.45 years, respectively. The mean EFW in case group was 1567.0 g with a standard deviation of 258.94, and in the control group was 1464.38 g with a standard deviation of 255.49. The mean LVT in the case group was 3.39 mm with a standard deviation of 0.32 and in the control group was 2.83 mm with a standard deviation of 0.27. The average number of RVT, IVS, RV Fractional shortening, LV Fractional shortening are shown in **Table.1**.

Table-1: Comparison between fetal cardiac structure in gestational diabetic and normal pregnancy groups.

Variables	Case group	Control group	P-value
Gestational age (week)	29.80±1.52	29.56±1.45	>0.05
EFW(gr)	1567.01±258.94	1464.38±255.49	>0.05
LVT(mm)	3.39±0.32	2.83±0.27	<0.001
RVT(mm)	3.46±0.35	2.88±0.27	<0.001
IVS(mm)	3.55±0.38	2.80±0.33	<0.001
RV.SF (%)	30.73±2.15	29.01±2.28	0.03
LV.SF (%)	2.44± 31.20	2.44±29.88	>0.05

EFW: estimated fetal weight, LVT: left ventricular thrombus, RVT: right ventricular thrombus, IVS: intact interventricular septum, RV.SF: right ventricular fraction shortening, LV: left ventricle.

The present study showed that there was a direct and significant relationship between right and left ventricle thickness and gestational diabetes mellitus (GDM) in the subjects (P<0.05). There was also a significant relationship between

interventricular septum and right ventricle shortening fraction with GDM in the subjects. However, there was no significant relationship between right ventricle shortening fraction and GDM (P> 0.05) (**Table.2**).

Table-2: The Pearson correlation between GDM and maternal parameters.

Variables	Group	Pearson correlation coefficient	P-value
Mother age, year	GDM	0.130	0.494
EFW	GDM	0.148	0.436
LVT	GDM	0.695	<0.001
RVT	GDM	0.685	<0.001
IVS	GDM	0.738	<0.001
Right ventricle fraction shortening	GDM	0.374	0.03
Left ventricle fraction shortening	GDM	0.274	0.134

GDM: gestational diabetes mellitus, EFW: estimated fetal weight, LVT: left ventricular thrombus, RVT: right ventricular thrombus, IVS: intact interventricular septum.

4- DISCUSSION

Extensive studies have been conducted to investigate the effect of maternal blood glucose on fetal heart health. The purpose of this study was to compare fetal cardiac echocardiography in healthy mothers and gestational diabetic

mellitus. A study found that maternal glucose levels were significantly altered in fetal heart, which was higher in mothers over 35 years and poorer control of treatment (6). It was found that high maternal glucose levels over 40 years of age had a poor fetal glucose control (7) on activity changes and higher fetal cardiac

structure (7). Various studies of fetal IVS thickness in gestational diabetes mothers have been higher than the control group; Gardiner et al., showed that good gestational diabetes control during pregnancy had similar findings to non-diabetic IVS thickness group (10). Wong and colleagues showed that there was no significant difference in IVS thickness between the good control and poor control groups, which is consistent with the present study (11). Chen et al.'s study showed that maternal hyperglycemia control could decrease fetal ventricular wall thickness in GDM mothers, but this effect was not statistically significant (12).

Tsutsumi et al. in their study showed RV, LV Global in the fetus. Diabetes mellitus (GDM) increased after week 27, which is consistent with the results of our study (13). In our study, left and right ventricular wall thickness was independent of EFW changes as a confounding factor in GDM subjects significantly ($P < 0.05$); which is consistent with the study of Tsutsumi et al. (13). Left and right ventricular wall thickness, right ventricle fraction shortening inter-ventricular septum, independent of EFW changes as confounding factor was significantly higher in GDM subjects than control group ($P < 0.05$).

In some other studies, such as the study by Eidem et al., there was no significant difference between the global cardiac measurement indices in diabetic and non-diabetic pregnancies, which was inconsistent with the results of our study (14). Another study by Wong et al. (2003) in diabetic pregnant women found that the Global Fetal Heart Index decreased after 34 weeks of gestation, which may be due to an increased likelihood of ventricular contractions (11). Chen et al. showed that hyperglycemia also causes diastolic dysfunction in the fetus of diabetic mothers, which changes with control of hyperglycemia RV indices earlier than LV

and is consistent with improved systolic and diastolic parameters (12).

5- CONCLUSION

Based on the results of the present study, it can be concluded that gestational diabetes mellitus in pregnant women can cause changes such as in the thickness of the ventricular wall of the fetus's heart which can have more severe consequences. Therefore, it is recommended that, because of the limited number of samples, this study should be reviewed in more cases, and strategies and training should be provided for the control of pregnant mothers' diabetes in order to avoid its complications.

6- ACKNOELEDGMENTS

The present article was extracted from the thesis written by Hadi Teimouri MD and was approved by the Ethics Committee of Ahvaz Jundishapur University (ID-code: IR.AJUMS.REC.1398.309).

7- CONFLICT OF INTEREST: None.

8- REFERENCES

1. Feng YJ, Shen K, Obstetrics and Gynecology. 1 st Edition .2005; Beijing: Peoples Health Press, 133. (In Chinese)
2. McAuliffe FM, Foley M, Firth R, Drury I, Stronge JM. Outcome of diabetic pregnancy with spontaneous labour after 38 weeks. *Ir J Med Sci* 1999;168:160-3.
3. Evers IM, de Valk HW, Visser GH. Risk of complications of pregnancy in women with type 1 diabetes: nationwide prospective study in the Netherlands. *BMJ* 2004; 328: 915.
4. Sheehan PQ, Rowland TW, Shah BL, Mc-Gravey VJ, Reiter EO. Maternal diabetic control and hypertrophic cardiomyopathy in infants of diabetic mothers. *Clin Pediatr* 1986; 25: 266-71.
5. Abu-Sulaiman RM, Subaih B. Congenital heart disease in infants of diabetic mothers: echocardiographic study. *Pediatr Cardiol* 2004; 25:137-40.

6. Halliday HL. Hypertrophic cardiomyopathy in infants of poorly-controlled diabetic mothers. *Arch Dis Child* 1981; 56: 258-63.
7. Reller MD, Kaplan S. Hypertrophic cardiomyopathy in infants of diabetic mothers: an update. *Am J Perinatol* 1988; 5: 353-8.
8. Veille JC, Sivakoff M, Hanson R, Fanaroff AA. Interventricular septal thickness in fetuses of diabetic mothers. *Obstet Gynecol*, 1992;79:51-4.
9. Gandhi JA, Zhang XY, Maidman JE. Fetalcardiac hypertrophy and cardiac function in diabetic pregnancies. *Am J Obstet Gynecol*, 1995;173:1132-36.
10. Gardiner HM, Pasquini L, Wolfenden J, et al. Increased periconceptual maternal glycated haemoglobin in diabetic mothers reduces fetal long axis cardiac function. *Heart*, 2006;92:1125-30.
11. Wong SF, Chan FY, Cincotta RB, et al. Cardiac function in fetuses of poorly-controlled pre-gestational diabetic pregnancies—a pilot study. *Gynecol Obstet Invest*,2003;56:113-6.
12. Chen C, Yong HG, Yun YR, Li YS. The Impacts of maternal Gestational Diabetes Mellitus (GDM) ON Fetal Hearts. *Biomed Environ Sci*. 2012; 25(1):15-22.
13. Tsutsumi T, Ishii M, Eto G, et al. Serial evaluation for myocardial performance in fetuses and neonates usinga new Doppler index. *Pediatr Int*.1999; 41,722-7.
14. Eidem BW, Edwards JM, Cetta f, Quantitative assessment of fetal ventricular function: establishing normalvalues of the myocardial performance index in the fetus. *Echocardiograph*. 2001;18: 9-13.