

## Survey of a Practical Approach to Central Venous Catheterization in Pediatric Patients

Alireza Mahdavi<sup>1</sup>, Ashkan Panah<sup>2</sup>, \*Afsaneh Sadeghi<sup>1</sup>

<sup>1</sup>Anesthesiologist, Anesthesiology Research Center (ARC), Shahid Beheshti University of Medical Sciences (SBMU), Tehran, Iran.

<sup>2</sup>Anesthesiologist, Shiraz University of Medical Sciences, Shiraz, Iran.

### Abstract

#### Background

Central venous catheter (CVC) is used for measuring hemodynamic variables, transfusion of blood, fluids and medications when peripheral vascular lack sufficiency. Unfortunately CVC is associated with many complications ranging from anxiety and discomfort for the patient to severe mechanical side effects such as arterial lacerations, pleural and pericardial injury as well as infection and thrombosis. This study aimed to survey of a practical approach to central venous catheterization in pediatric patients.

#### Materials and Methods

In this retrospective and descriptive study, rate of success and complications of central venous catheterization by the anesthesia team for the hospitalized children 0-15 years from 2009 to 2016 years at Mofid Children Hospital, Tehran-Iran, were investigated. Advancement of catheters tips in pleural space; peritoneal cavity and pericardium were recognized by rat tail blood flow as a practical approach which was proved by chest X- ray. Successful rate and complications of inserting CVC were collected by researchers using medical records of the patients.

#### Results

There were 2,385 (53%) female and 2,115 (47%) male patients. Patient's age ranged from 1 month to 10 years, mean  $12.25 \pm 6.45$  months. About 4,500 patients who underwent central venous catheterization were investigated that 815 patients (18%) had improper catheterization in the internal jugular and 374 patients (8%) had accidental arterial injury and 160 patients (3%) had accidental pleural injury. Accidental pleural injury were recognized by rat tail blood flow in the liquid column connected to the catheter to the patient's bedside and all of them was proven by taking control image.

#### Conclusion

Using rat tail blood flow as a practical approach to central venous catheterization in pediatric patients can be associated with prevention of the plural injury and subsequent pneumothorax and hemothorax.

**Key Words:** Central Venous Catheters, Pediatrics, Pneumothorax.

\*Please cite this article as: Mahdavi A, Panah A, Sadeghi A. Survey of a Practical Approach to Central Venous Catheterization in Pediatric Patients. Int J Pediatr 2018; 6 (6): 7843-49. DOI: [10.22038/ijp.2018.29953.2649](https://doi.org/10.22038/ijp.2018.29953.2649)

#### \*Corresponding Author:

Afsaneh Sadeghi (MD), Pediatric Anaesthesiology Mofid Hospital, Shahid Beheshti University of Medical Sciences, Tehran, Iran; Institution Address: Mofid Pediatric Hospital, St, Tehran, Iran.

Email: are20935@yahoo.com

Received date: Feb:10, 2018; Accepted date: Mar: 22, 2018

## 1- INTRODUCTION

Inserting a central venous catheter in surgical patients admitted to the intensive care unit (ICU) takes place frequently (1). In the United States of America, for example, approximately five million central venous catheters are inserted annually, which include 8% of hospitalized patients (2). Catheterization is utilized for such cases as fluid therapy, lack of adequate access to peripheral vascular, administration of vasoactive drugs and the need to hypertonic fluids such as total parenteral nutrition (TPN), chemotherapy and concentrated electrolyte liquid such as potassium and cases like hemodialysis or measuring variables such as central venous pressure or repeated blood sampling (3). There is no absolute contraindication for the use of this device, except for such relative cases as infection or clotting problems, which can be done regarding numerous places available to central venous (3).

Catheter site selection depends on various factors such as experience and skill of the operator or the patient's anatomy and hazards such as coagulation disorders, lung problems and other comorbid conditions (4). However, the highest success and the lowest risk of mechanical complication rely on the experience and skill of the catheter operator (5). Typical veins for the insertion of central venous catheter include: internal and external jugular vein, subclavian and femoral vein. The right place for the catheter tip in the veins of the lower body are in the inferior vena cava and for the upper torso, are in the superior vena above the right atrium are used (6). To confirm the suitability of the catheter tip, X-rays, ultrasound, fluoroscopy or transesophageal echocardiography in particular for intraoperative cases are used (6). Common complication of central venous catheterization is infection and thrombosis. Less common but serious side effect is mechanical damage that usually

occurs during catheterization (7). The experience and skill of the operator, selecting the right area, sterility and the use of ultrasound are highly effective in reducing complications (2). Some of these effects could be noted as misplaced insertion in the arteries, pleura, pericardium, sustainable hemorrhage, pneumothorax, chylothorax, hemothorax, pleural effusion, pericardial effusion and cardiac tamponade, pulmonary embolism and trachea damage (8, 9). In the event of damage to the thoracic duct, there is chance of chylothorax that is possible in the approach to the subclavian vein (10, 11). Mind's eye visualization of proper placement location not only increases the safety of the procedure but also enhances the operator's ability to troubleshoot difficult catheterization (12). Furthermore, several case reports recommended a practical approach to CVC insertion to prevention of complication, which do not provide pragmatic guidance or solutions to the problem (13). Therefore there is not a reliable method to diagnosis of the improper catheterization during procedure. This study aimed to survey of a practical approach to central venous catheterization in pediatric patients.

## 2- MATERIALS AND METHODS

### 2-1. Study design and population

In this retrospective and descriptive study, rate of success and complications of central venous catheterization by the anesthesia team for the hospitalized children 0-15 years from 2009 to 2016 years at Mofid Children Hospital, Tehran-Iran, were investigated.

### 2-2. Methods

The same team of anesthesiologist was responsible for all the cases in our study, and all CVC insertion and investigations about CVC complications and successful placement was done by this team.

Method of work was so that after entering the child into the operating room anesthetic induction was done with sevoflurane in a way that preserved spontaneous breathing. Full monitoring of Pulse oximetry, heart monitor, blood pressure and capnography was established and the specific catheter kit was selected in sterile conditions including wearing mask, cap, sterile gown and gloves after washing hands for 3-5 minutes and disinfection and then the sets for central venous catheter insertion opened.

The patient lied in the Trendelenburg position at an angle of 10-15 degrees, head was turned to the opposite side and shoulder roll was placed. The operator stands beside the location of the catheterization, the catheter along with the front part was completely disinfected and large sterile drape was spread in place. Using infraclavicular approach right on the midclavicular or slightly lateral to it at an angle of 0-5 degrees to the sternal notch, the syringe and needle enter in aspiration mode. When the vein was punctured and blood was aspirated, the syringe was isolated and in the absence of pulsatile blood flow, the needle was kept completely fixed by hand. The other partner enters guidewire through the needle without the slightest pressure and resistance. If there was resistance to the guidewire, it was pulled out and the operation was repeated. If the vein was not punctured, the needle was pulled back under the skin and slightly advances more cephalad to the sternal notch and operation was repeated. After passing the guidewire, the needle was pulled out, a small incision was created in the area and using dilators the area was dilated as tract on a rotating basis. If arterial line catheters were used, there was no need for dilators (8). Catheter was inserted over the guidewire and by estimating the distance to the right atrium, the catheter is pushed forward and the guidewire was removed.

By aspirating blood, air inside the catheter was depleted and the liquid was injected by syringe and the catheter was closed and fixed with suture. Anesthesia team connected the liquid column to the catheter and set the liquid source a little above the surface of the body, and by lack of increasing blood flow and lack of pulsed blood flow in the catheter they ensure that the catheter is not in the artery. Obviously, if the patient is severely ill and has underlying disease leading to hypotension (e.g. shock) even if the liquid source was at a higher level of the body, it was possible that the increasing blood flow was not observed due to overcome of the pressure of the liquid column to the patient's blood pressure, and this shall be noted. By lowering the source beneath the surface of the body and the existence of decreasing blood flow as rat tail (**Figure.1**), the lack of catheter in the pleura and pericardia was ensured and after the establishment of the necessary conditions for discharge from the operation room the chest X-ray was performed for reassurance from the appropriate insertion of the catheter and the administration of fluids and drugs from the catheter was permitted.

### **2-3. Measuring tools**

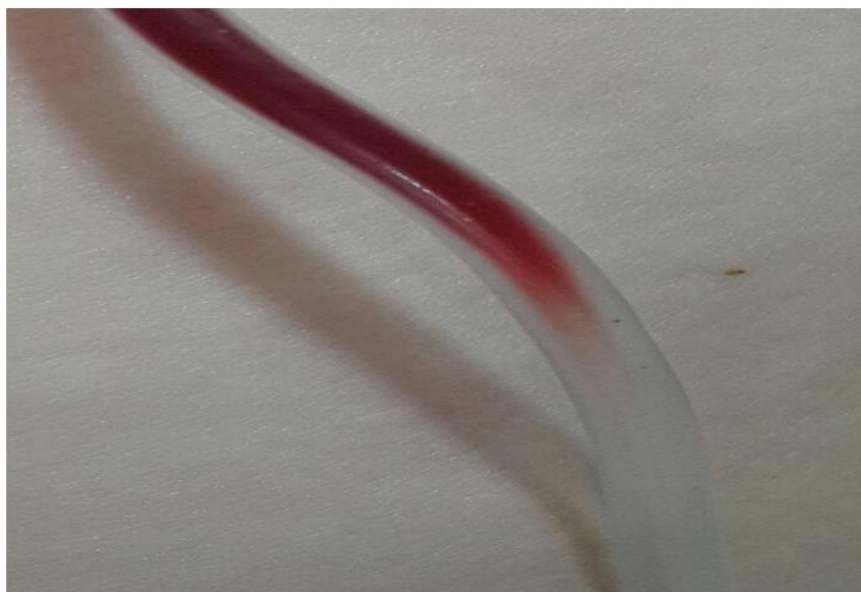
Demographic data and complications and rate of success of CVC insertion were collected by researchers from hospital archive department using medical records of the patients.

### **2-4. Ethical consideration**

The study was reviewed and approved by the university review board and hospital ethics committee.

### **2-5. Data Analyses**

Data analysis was done by SPSS version 22.0 software and through descriptive statistic.



**Fig1:** Positive rat tail sign. It means that the tip of catheter is in the vessel.

### 3- RESULTS

This study aimed to survey of a practical approach to central venous catheterization in pediatric patients referred to Mofid Hospital, Tehran, Iran. In present study, 4,500 patients were investigated that all of them included into the study. There were 2,385 (53%) female and 2,115 (47%) male patients. Patient's age ranged from 1 month to 10 years, mean  $12.25 \pm 6.45$  months. A

mong them, 815 patients (18%) were reported with improper placement of the catheter in the internal jugular and the cases were proven using the chest X-ray. In 374 patients (8%) accidental artery injury occurred of which 300 (80.2 %) cases were proven by observing a bright and pulsating blood flow at the time of injury and 70 (18.7%) cases were proved by rising blood column in the catheter connected to a liquid source from body level after catheterization and only in 4 (1.1%) cases \_ all of which were in septic

shock after capturing a chest X-ray-catheter insertion to the heart's left side were found. In 160 patients (3%) the accidental pleural injury occurred that in 150 cases by aspirating air bubble due to suspicion to pleural damage, the catheter was immediately changed and in 10 cases despite aspirated blood and blood flow in the catheter connected to a liquid source, no rat tail blood flow was observed and in all cases blood columns were completely observed separated from the liquid column with clear boundary (**Figure.2**).

For the cases that were suspected to pleural damage, chest X-ray was performed and in all cases the pleural damage and the insertion of catheters in pleura was proved. In the other hand, rat tail blood flow was observed in all cases that CVC insertion was successful and also in cases that catheter inserted in plural cavity, rat tail was not observed.



**Fig.2:** Negative rat tail sign. It means that the tip of catheter is not in the vessel and is on other place such as plural and pericardium.

#### 4- DISCUSSION

Subclavian catheterization in children has been well described in various articles and they are beneficial. With regard to fixed anatomical location, it is easy to maintain them and the children feel more comfortable; and considering the movement of children, the possibility of changing and moving the catheter tip is less (10). The traditional method for subclavian catheterization is blind and observing it with ultrasound is difficult. The key to success in the blind method is knowledge of the anatomic relationship between the clavicle and subclavian vein (10). When the shoulder is in neutral position, subclavian vein in the middle third of clavicle overlaps with it (14). Finck et al. studied 110 cases of subclavian catheterization in children under one year. There were 78.8% successful catheterizations in children under 6 months and 96% successful cases in children over 6 months. The authors did not mention any side effects. Based on the experience and skills and anatomical position, they recommended that the primary action shall be the left subclavian catheters and if they fail, the next step is right internal jugular vein (11). Citak et al. also inserted 148 subclavian catheters for children between

1 month to 14 years in the intensive care unit (ICU) and emergency room (ER) and 100% of the cases were successful. (15). Eichelberger et al. performed 191 cases of catheterizations in infants to 20 month children without any mechanical problems (16). The chance of subclavian catheter infection in the studies have been clearly lower than femoral catheterizations (16), and in other studies subclavian catheter infection has been reported less than the internal jugular catheterizations (17). The chance of thrombosis in the subclavian catheter compared with femoral catheters has been reported 1.9 % and 21.5%, respectively (18). In addition, in an observational study, the chance of thrombosis of the internal jugular vein has been reported 4 times more than the subclavian vein (19). However, Sheridan and Weber in a retrospective study on 1,056 children aged 4-6 years hospitalized in children's burns ward, reported 23% thrombosis of the subclavian vein, 11% internal jugular vein and 66% femoral vein (20). The chance of injury to the arteries in the classical and blind method for subclavian approach is reported 14% (21). Citak et al. have mentioned the chance of arterial injury 12.8% (15). In patients with normal blood pressure and appropriate

blood oxygen concentration diagnosis of arterial puncher and access is possible by observing the pulsatile and increasing blood column and bright color of the blood. In patients with low blood pressure, it can be difficult to diagnose the differentiation of venous and arterial blood but it is possible by connecting the catheter to a pressure transducer and observing the resulting wave measurements. Moreover, with a catheter blood sampling and comparing it with arterial blood sample, the observation of the difference in oxygen concentration of the blood samples can also help to select the appropriate area for the catheter (2). Breathing spontaneously causes Intrathoracic negative pressure inside the chest during the inhalation and if the catheter is left open in the room, pulling a little air into the catheter can cause air embolism. Even a small amount of air can be fatal; especially if the patient has atrial or ventricular wall defects. For this reason the patient should be in Trendelenburg position at the time of central venous catheterization and the catheter air shall be drained and washed and the catheter hub shall always remain closed (2). Pleural injury and subsequent pneumothorax and hemothorax in subclavian approach have been reported 6% (21). In the case of inadvertent insertion of catheters in pleural space, peritoneal cavity and pericardium, blood could be aspirated with low pressure and slowly. The blood oxygen concentration is similar to systemic circulation if associated with a pneumothorax but the difference is lack of coagulation (6). Anesthesia team at Mofid Children Hospital benefitted of this property for visualization of blood flow tapering and tiny blood as rat tail return to fluid tube when the bottle is placed below the patient level for correct subclavian intravenous catheter placement. In pleural space or other places than subclavian vein placement of catheter, blood returned in fluid tube could be bright, plasma like and homogeneous with clear boundary. It is

important for operators to note this difference and not just check the blood return into fluid tube. There is possibility of venous catheter malposition, especially into the opposite brachiocephalic vein or internal jugular on the same side. It is possible that the catheter enters into the internal jugular vein especially in children in an effort to right subclavian catheterization due to more acute angle between the subclavian vein and an innominate vein compared to adults, that the chest x-ray after the operation can show this well (10). If catheter enters into a misplaced vein, its use is permitted for hydration, but as soon as the emergency elimination, it is better to change the catheter place because of increased chances of thrombosis (22).

#### **4-1. Limitations of the study**

One of the limitations of our study was study design that we recommend clinical trials and prospective study to confirm our finding.

#### **5- CONCLUSION**

Since, pleural injury and subsequent pneumothorax and hemothorax may be associated with life threatening complications, according to our finding, applying the rat tail blood flow as a practical approach to identify the insertion of catheters in pleural space in pediatric patients is recommended.

**6- CONFLICT OF INTEREST:** None.

#### **7- REFERENCES**

1. Ghods K, Razavi MR, Forozeshfard M. Performance, pain, and quality of life on use of central venous catheter for management of pericardial effusions in patients undergoing coronary artery bypass graft surgery. *Journal of pain research*. 2016; 9: 887.
2. McGee DC, Gould MK. Preventing complications of central venous catheterization. *N Engl J Med*. 2003 Mar 20; 348(12):1123-33.

3. Ruesch S, Walder B, Tramèr MR. Complications of central venous catheters: internal jugular versus subclavian access--a systematic review. *Crit Care Med.* 2002 Feb; 30 (2): 454-60.
4. Plumhans C, Mahnken AH, Ocklenburg C, Keil S, Behrendt FF, Günther RW, et al. Jugular versus subclavian totally implantable access ports: catheter position, complications and intrainterventional pain perception. *Eur J Radiol.* 2011; 79(3): 338-42.
5. Sznajder JI, Zveibil FR, Bitterman H, Weiner P, Bursztein S. Central vein catheterization. Failure and complication rates by three percutaneous approaches. *Arch Intern Med.* 1986; 146(2):259-61.
6. Gibson F, Bodenham A. Misplaced central venous catheters: applied anatomy and practical management. *Br J Anaesth.* 2013; 110(3):333-46
7. Francis KR, Picard DL, Fajardo MA, Pizzi WF. Avoiding complications and decreasing costs of central venous catheter placement utilizing electrocardiographic guidance. *Surg Gynecol Obstet.* 1992 Sep; 175 (3):208-11.
8. de Jonge RC, Polderman KH, Gemke RJ. Central venous catheter use in the pediatric patient: mechanical and infectious complications. *Pediatr Crit Care Med.* 2005; 6 (3):329-39.
9. Noripour S, Molaei A, Bandari R, Emadi A, Far SMF, Forozeshfard M. Comparison of the Results of Simultaneous Surfactant Administration and Nasal Continuous Positive Airway Pressure (INSURE) and Non-administration of Surfactant for the Treatment of Infants with Respiratory Distress Syndrome. *Journal of Comprehensive Pediatrics.* 2017; 8(1): e37462.
10. Aminnejad R, Razavi SS, Mohajerani SA, Mahdavi SA. Subclavian Vein Cannulation Success Rate in Neonates and Children. *Anesth Pain Med.* 2015; 5(3):e24156.
11. Finck C, Smith S, Jackson R, Wagner C. Percutaneous subclavian central venous catheterization in children younger than one year of age. *Am Surg.* 2002; 68(4):401-4.
12. Bannon MP, Heller SF, Rivera M. Anatomic considerations for central venous cannulation. Risk management and healthcare policy. 2011; 4: 27.
13. Wang L, Liu Z-S, Wang C-A. Malposition of central venous catheter: presentation and management. *Chinese medical journal.* 2016; 129(2): 227.
14. Tan BK, Hong SW, Huang MH, Lee ST. Anatomic basis of safe percutaneous subclavian venous catheterization. *J Trauma.* 2000; 48(1):82-6.
15. Citak A, Karaböcüoğlu M, Uçsel R, Uzel N. Central venous catheters in pediatric patients--subclavian venous approach as the first choice. *Pediatr Int.* 2002; 44(1):83-6.
16. Eichelberger MR, Rous PG, Hoelzer DJ, Garcia VF, Koop CE. Percutaneous subclavian venous catheters in neonates and children. *J Pediatr Surg.* 1981; 16(4 Suppl 1):547-53.
17. Merrer J, De Jonghe B, Golliot F, Lefrant JY, Raffy B, Barre E, et al. Complications of femoral and subclavian venous catheterization in critically ill patients: a randomized controlled trial. *JAMA.* 2001; 286(6):700-7.
18. McKinley S, Mackenzie A, Finfer S, Ward R, Penfold J. Incidence and predictors of central venous catheter related infection in intensive care patients. *Anaesth Intensive Care.* 1999; 27(2):164-9.
19. Timsit JF, Farkas JC, Boyer JM, Martin JB, Misset B, Renaud B, et al. Central vein catheter-related thrombosis in intensive care patients: incidence, risks factors, and relationship with catheter-related sepsis. *Chest.* 1998; 114(1):207-13.
20. Sheridan RL, Weber JM. Mechanical and infectious complications of central venous cannulation in children: lessons learned from a 10-year experience placing more than 1000 catheters. *J Burn Care Res.* 2006; 27(5):713-8.
21. Casado-Flores J, Valdivielso-Serna A, Pérez-Jurado L, Pozo-Román J, Monleón-Luque M, García-Pérez J, et al. Subclavian vein catheterization in critically ill children: analysis of 322 cannulations. *Intensive Care Med.* 1991; 17(6):350-4.
22. Guilbert MC, Elkouri S, Bracco D, Corriveau MM, Beaudoin N, Dubois MJ, et al. Arterial trauma during central venous catheter insertion: Case series, review and proposed algorithm. *J Vasc Surg.* 2008; 48(4):918-25; discussion 925.