

Cardiac Involvement in Mild Cystic Fibrosis Lung Involvement Assessed by Tissue-Doppler Echocardiography

Mehdi Ghaderian¹, Majid Keivanfar², Shiva Barani Beiranvand³, *Mohsen Reisi²

¹Pediatric Cardiovascular Research Center, Cardiovascular Research Institute, Isfahan University of Medical Sciences, Isfahan, Iran. ²Pediatric pulmonology Department, Child Growth and Development Research Center, Research Institute for Primordial Prevention of Non-Communicable Disease, Emam Hossein Children's Hospital, Isfahan University of Medical Sciences, Isfahan, Iran. ³Pediatric Cardiovascular Research Center, Cardiovascular Research Institute, Isfahan University of Medical Sciences, Isfahan, Iran.

Abstract

Background: Cystic Fibrosis (CF) is a systemic disease affecting extra pulmonary dysfunction as a result of CF-related lung disease. Because of lack of enough studies in this field and utilization of TDE in this field, we aimed to evaluate the cardiac involvement in children with CF and compare it with healthy children.

Materials and Methods: In this cross sectional study, children diagnosed with cystic fibrosis aged less than 15 years who referred to Emam Hossein Children's Hospital, affiliated to Isfahan University of Medical Sciences, Iran, during 2018, were enrolled. Participants were 2 groups: case and control. In this study 27 children with mild cystic fibrosis lung disease and 27 healthy children were evaluated. Case groups were consisted of children with CF, and control group were healthy children. FEV1, FVC, and FEV1 / FVC of all participants were recorded based on their spirometry findings. Cardiac function tests including electrocardiogram and Doppler echocardiography were evaluated by an expert pediatric cardiologist. Spirometry and Doppler echocardiography findings in two studied groups were compared.

Results: Lateral wall tissue Doppler echocardiographic evaluation, annular peak velocity during systole and E'/A' ratio was significantly higher in children with CF than healthy children (P<0.05). In the right ventricle (septal wall) tissue Doppler echocardiographic evaluation peak velocity during early diastole, peak velocity during late diastole and annular peak velocity during systole was significantly higher in healthy children than those with CF (P<0.01). E'/A' ratio in the right ventricle (septal wall) tissue Doppler echocardiographic evaluation was significantly higher in children with CF than healthy children (P<0.01).

Conclusion

Based on the results, it is recommended to consider tissue Doppler echocardiography in the earlier period of CF patients' follow-up program.

Key Words: Children, Cystic fibrosis, Spirometry, Tissue Doppler echocardiography.

*Please cite this article as: Ghaderian M, Keivanfar M, Barani Beiranvand Sh, Reisi M. Cardiac Involvement in Mild Cystic Fibrosis Lung Involvement Assessed by Tissue-Doppler Echocardiography. Int J Pediatr 2019; 7(10): 10205-214. DOI: **10.22038/ijp.2019.41556.3502**

*Corresponding Author:

Mohsen Reisi (M.D), Pediatric Pulmonology Department, Emam Hossein Children's Hospital, Isfahan University of Medical Sciences, Isfahan, Iran.

Email: Mohsenreisi72@yahoo.com

Received date: Mar.17, 2019; Accepted date: Aug.22, 2019

1- INTRODUCTION

Cystic fibrosis (CF) is an autosomal recessive life-shortening disorder that results from mutations in the cystic fibrosis transmembrane conductance regulator (CFTR) gene (1). CFTR is an ion channel regulating transporter of chloride, bicarbonate, and water, and influencing sodium resorption (2). CF mainly presents with respiratory and gastrointestinal diseases including chronic airway obstruction, infertility, intestinal malabsorption and exocrine pancreatic insufficiency but its related morbidity and mortality is commonly due to progressive pulmonary disease (3, 4). Evidence indicated that CF is related with cardiac dysfunction including both right and left ventricular abnormalities. Cardiac fibrosis (CF), a main process of ventricular remodeling after myocardial infarction (MI), plays a crucial role in the pathogenesis of heart failure (HF) post-MI (5), CFTR is widely distributed in nucleated cells, including cardiac myocytes, but the effect of genotype on cardiac function is not known (6).

Right ventricular abnormalities are mostly manifested by pulmonary hypertension. Other reported abnormalities are decreased septal and lateral strain rates due to pulmonary impairment. Left ventricular abnormalities are myocardial wall thickness and increased LV chamber size (7-9). Given that CFTR disruption could impair myocyte contractility and cardiac function, it is not clearly determined whether CF related cardiac dysfunction is the result of systemic loss of CFTR or is a secondary complication of CF and its related hypoxia, inflammation and increased cytokines secretion in the pulmonary tissue (8). Recent studies indicated that the subclinical cardiac dysfunction is already present in affected patients during the early stages of CF (10-12). Thus, in order to improve the quality of care and reduce CF related co-

morbidities, cardiac function evaluation is recommended as a routine follow-up item (12). Different diagnostic modalities are used in this field including MRI, or echocardiography (13). Echocardiography is one of the most commonly used diagnostic modalities due to its low cost and feasibility for use during follow up periods but it has some limitations which lead to providing its new features including Tissue Doppler Echocardiography (TDE) which could perform more accurate examination of both left and right ventricles and their movements during systole and diastole. Some studies have reported its performance for investigation of early onset cardiac abnormalities (14, 15).

Considering that diagnosis and management of cardiac dysfunctions in CF patients as one of the most important extra-pulmonary comorbidities could improve the length and quality of life of CF patients and lack of enough studies in this field especially in children and adolescents who are in the earlier stage of the disease and effectiveness of TDE in this field, we aimed to evaluate the cardiac involvement in children with CF and compare it with healthy children.

2- MATERIALS AND METHODS

2-1. Study design and population

In this cross sectional study, children diagnosed with cystic fibrosis aged less than 15 years who referred to Emam Hossein Children's Hospital, affiliated to Isfahan University of Medical Sciences, Iran, and during 2018 were enrolled. The study lasted 12 months. Participants were 2 groups: case and control. In this study 27 children with mild cystic fibrosis lung disease and 27 healthy children were evaluated. Case groups consisted of children with cystic fibrosis, and control group were healthy children, who referred to hospital for check-up.

2-2. Methods

Demographic, anthropometric and medical data consisting of age, sex, height, weight, body mass index (BMI), blood pressure, systolic and diastolic enrolled participants were recorded by an expert pediatric cardiologist in Emam Hossein Children's Hospital, affiliated to Isfahan University of Medical Sciences, Iran. All of the participants were clinically examined. Chest X-ray and spirometry were performed for all enrolled children. Those with abnormal chest X-ray findings were excluded. Forced expiratory volume (FEV1), Forced vital capacity (FVC), and FEV1 / FVC of all participants were recorded based on their spirometry findings. According to the ATS/ERS guidelines those with FEV1% values >70% were classified as having mild pulmonary disease (16, 17). Cardiac function tests including electrocardiogram and Doppler echocardiography was evaluated by an expert pediatric cardiologist (MGh). Spirometry and Doppler echocardiography findings in two studied groups were compared.

2-3. Measuring tools OR Laboratory measurements

Tissue Doppler echocardiography

Tissue Doppler echocardiography was performed in all patients and control healthy children using M-mode, 2D and Doppler echocardiography using Medison EKO7 / Korea echo and 3 to 7 MHz transducers. The thickness of the right ventricle free wall and the interventricular septum was measured. With the pulse-wave Doppler sample volume placed at the tip of the tricuspid valve during diastole filling velocity was recorded from the apical four-chamber view. The peak velocity early diastole (E), peak velocity late diastole (A), deceleration time (DT) of the early diastolic velocity and E/A ratio were measured. The velocity of the right ventricle walls using the Tissue-Doppler

mode is measured in echocardiography at systolic and diastolic times in apical four-chamber view, and the peak systolic (S'), and early and late diastolic velocities (E' and A') were measured. The echocardiography marker will be located at the interface between the tricuspid valve and the right lateral ventricular wall and at the interface between the tricuspid valve and the interventricular septum. The Ejection Time (ET) is calculated from the beginning of the S wave to the end of this wave. The measurements of at least three cardiac cycles were averaged in sinus rhythm. The index of myocardial performance index (MPI) is also calculated from the total isovolumic contraction time (ICT) from the end of tricuspid flow to the beginning of pulmonary flow plus isovolumic relaxation time (IRT) from the end of the S-wave to the beginning of E-wave divided by ET ($ICT + IRT / ET$).

The pulmonary artery pressure is calculated from the gradient between the tricuspid valve and the right atrium or pulmonary regurgitation wave during diastole time (this pressure should be normal). End-systolic and end-diastolic dimensions of the left ventricle, interventricular septum, anterior wall thickness, and end-diastolic dimension of the right ventricle were measured at the parasternal long axis view. Fractional shortening (FS) was calculated (LV diastolic internal dimension- LV systolic internal dimensions/ LV diastolic internal dimension) and ejection fraction (EF) at the papillary muscle in parasternal long axis view.

2-4. Ethical consideration

The protocol of this study was approved by Pediatrics Board Review members and Regional Ethics Committee of Isfahan University of Medical Sciences with a research project number of: IR.MUI.MED.REC.1397.062. Written informed consent forms were completed by all participants and/or their parents

before study and after explaining about the aim of the study and the methods of the research.

2-5. Inclusion and exclusion criteria

Children were diagnosed by researcher with cystic fibrosis aged less than 15 years were entered in this study, also patients with mild CF lung disease were included and those with history of any systemic or cardiovascular disease and whose parents declined to cooperate were excluded.

2-6. Data Analyses

Obtained data from the encoded checklist were analyzed using SPSS software version 20.0 (IBM, Armonk, NY, USA). Normal distribution of the studied variables was evaluated by Kolmogorov-Smirnov statistical tests. Quantitative variables were presented as mean (SD) and were compared in the studied groups using Student T-test. The association between studied variables was evaluated by Pearson's Correlation test. P-value less than 0.05 was considered statistically significant.

3- RESULTS

In this study 27 children with mild cystic fibrosis lung disease and 27 healthy children were enrolled. Demographic and clinical findings of the study population are presented in **Table.1**. There were not significant differences between the groups regarding the variables ($P>0.05$).

Echocardiographic findings of the study population in the two groups are presented in **Table.2**. Free RV wall thickness was significantly thicker in children with CF than healthy children ($P<0.01$). Comparison of Conventional Echo Tricuspid in two groups is presented in **Figure.1**. In the right ventricle (lateral wall) tissue Doppler echocardiographic evaluation annular peak velocity during systole (S'), and E'/A' ratio was significantly higher in children with CF than healthy children ($P<0.05$). Comparison TDE of RV at tricuspid in Lateral wall in two groups is presented in **Figure.2**.

In the right ventricle (septal wall) tissue Doppler echocardiographic evaluation peak velocity during early diastole (E'), peak velocity during late diastole (A') and annular peak velocity during systole (S') was significantly higher in healthy children than those with CF ($P<0.01$). E'/A' ratio in the right ventricle (septal wall) tissue Doppler echocardiographic evaluation was significantly higher in children with CF than healthy children ($P<0.01$). TDE comparison of RV at tricuspid in septal wall in two groups is presented in **Figure.3**. Left ventricular fractional shortening (LV-FS) was significantly higher in healthy children than those with cystic fibrosis ($P<0.01$). The spirometry values of the study population in the two groups are presented in **Table.3**. The values were not significantly different between groups.

Table-1: Demographic and clinical findings of children with mild cystic fibrosis and healthy children.

Variables	Children with cystic fibrosis, n=27	Healthy children, n=27	P-value
Age (years)	10.59(1.44)	10.92 (1.41)	
Gender (n)			
Male/Female	14/13	13/14	
Height (cm)	138 (8.2)	140 (8.1)	0.39
Body weight (kg)	34.33(6.71)	34.77 (5.17)	0.78
Body Mass Index BMI (Kg/M ²)	20.66 (2.01)	20.33 (1.77)	0.52
Heart rate (beat/min)	83.18 (7.93)	84.81 (10.84)	0.53
Respiratory rate (breath/min)	19.59 (2.83)	19.25 (2.65)	0.65
Blood Pressure (mmHg)			
Systolic	106.85 (8.11)	111.11 (8.47)	0.66
Diastolic	60.74 (7.80)	62.96 (8.23)	0.32

Table-2: Echocardiographic findings of children with mild cystic fibrosis and healthy children.

Variables	Children with cystic fibrosis, n=27	Healthy children, n=27	P-value
Conventional Echo			
Tricuspid			
E velocity (cm/s)	106.29(21.68)	98.88 (21.72)	0.21
A velocity (cm/s)	62.59 (26.97)	63.51(26.37)	0.89
E/A ratio	1.72(0.46)	1.63(0.43)	0.43
Free RV wall thickness (22)	4.72(0.1)	3.58(0.19)	0.00
RV diameter (22)	16.4 (2.1)	16.55 (2.37)	0.85
TDE of RV at tricuspid			
Lateral wall			
E' velocity (cm/s)	16.88(4.47)	16.11(1.71)	0.40
A' velocity (cm/s)	10.18(3.35)	10.40(1.42)	0.75
E'/A' ratio	1.70(0.42)	1.44(0.11)	0.03
S'	13.03(4.39)	11.22(0.89)	0.04
Septal wall			
E' velocity (cm/s)	13.22(2.50)	15.40(1.18)	0.00
A' velocity (cm/s)	7.00(1.54)	10.77(1.52)	0.00
E'/A' ratio	1.88(0.22)	1.43(0.13)	0.00
S'	8.88(2.39)	11.7(1.7)	0.00
DT (ms)	135.0 (21.79)	129.81(18.31)	0.34
Tie-index (MPI (%))	45.77%(10.67)	44.81%(5.79)	0.68
IVRT	55.81 (7.49)	56.11 (7.44)	0.88
IVCT	52.33 (4.1)	52.11(4.06)	0.84
LV-EF (28)	69.44(4.20)	69.22(3.85)	0.84
LV-FS (28)	38.37(2.57)	40.07 (1.97)	0.00

A: peak velocity during late diastole, E: peak velocity during early diastole, A': Annular peak velocity during late diastole, E': Annular peak velocity during early diastole, S': Annular peak velocity during systole, DT: deceleration time, ms; millisecond, MPI: Myocardial performance index, IVRT: isovolumetric relaxation time, IVCT: isovolumetric contraction time, LVEF: left ventricular ejection fraction, LV-FS: left ventricular fractional shortening.

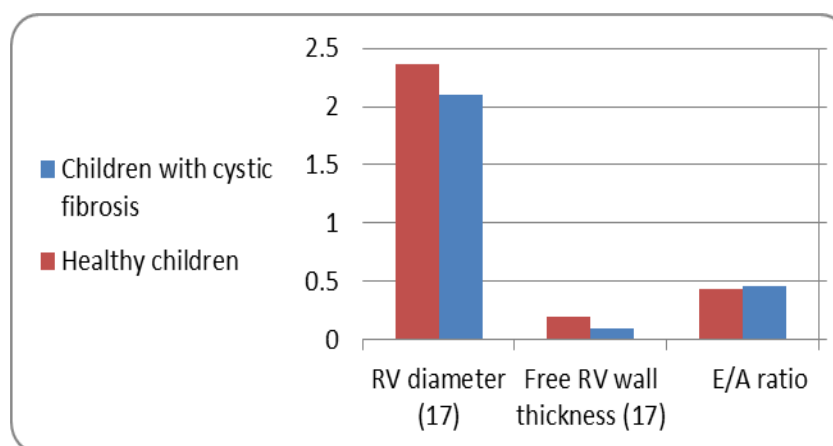


Fig.1: Comparison of Conventional Echo Tricuspid in two groups. (RV: Right ventricular).

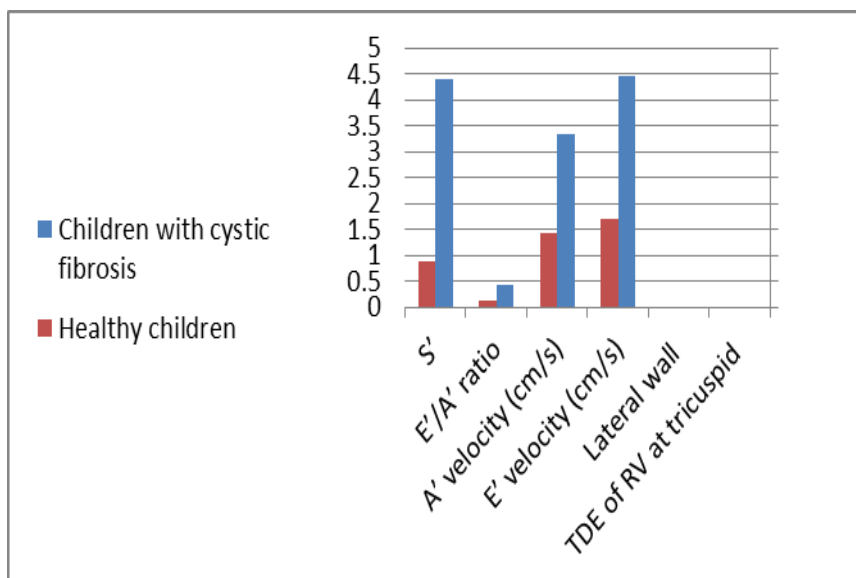


Fig.2: Comparison TDE of RV at tricuspid in Lateral wall in two groups. (TDE: tissue Doppler echocardiography RV: Right ventricular).

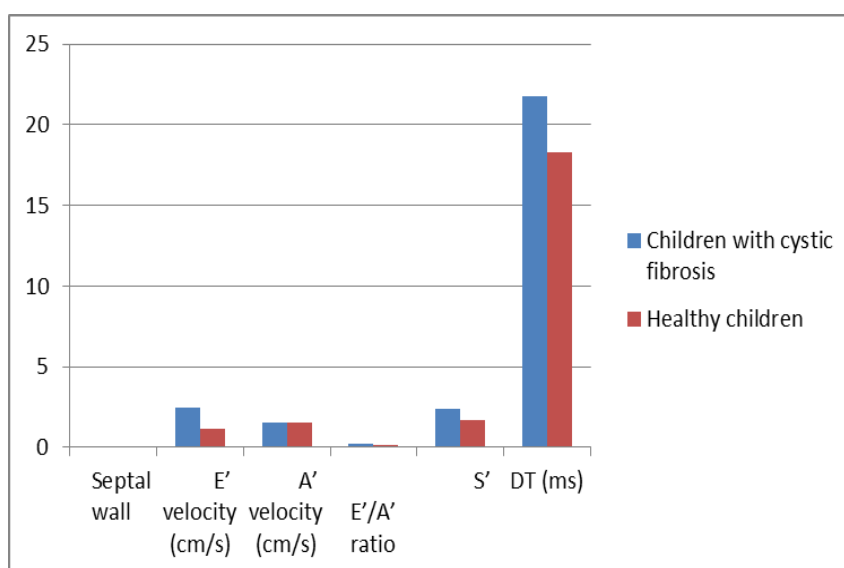


Fig.3: TDE comparison of RV at tricuspid in septal wall in two groups. (TDE: tissue Doppler echocardiography RV: right ventricular).

Table-3: The spirometry values of children with mild cystic fibrosis and healthy children.

Spirometry values	Children with cystic fibrosis	Healthy children	P-value
FEV1	88.2(13.7)	96.2 (15.4)	0.68
FVC	90.6 (14.1)	99.2 (16.1)	0.82
FEV1/FVC	89.9 (13.9)	97.7(15.7)	0.75

PEF: peak expiratory flow, FEV1: forced expiratory volume in 1 s, FVC: forced vital capacity, FEV1/FVC: the ratio of FEV1 to FVC.

4- DISCUSSION

In present study, CF patients with mild lung disease were studied. In our study both conventional and new echo-indexes were evaluated and compared with the control group. Lung tests were also performed. Patients did not have abnormal pulmonary pressure, and EF did not differ significantly with the control group ($P=84\%$). However, there was a significant difference in FS between these patients and controls, and significant differences were observed between E 'and A' in the interventricular septum and S 'in the right ventricular free wall significantly ($P<0.05$). There was a clear difference in the lateral ventricular free wall thickness. Compared to other studies, changes in the right ventricular wall appear before the obvious pulmonary symptoms or pulmonary hypertension (10) are begun, and these changes have not yet been sufficiently influenced by conventional tools, such as two-dimensional echocardiography or m-mode.

Chronic obstructive pulmonary disease was associated with intra and interventricular dyssynchrony (18). These changes in the ventricular wall can be non-symmetric and, therefore, do not disturb all of the indexes and our study results confirm this. In our study, the IVRT, IVCT, and Tie-index indices did not show a significant difference with the control group and indicate good systolic function in these patients. There was no significant difference in the diastolic function of the tricuspid valve and the E and A waves in these patients ($P>0.05$). Several studies have been used to investigate lung function and cardiopulmonary function in CF patients, including the use of CT scan, MRI or imaging echocardiography (19-23). Prolonged survival of cystic fibrosis favors heart and vessel involvement (24). Some studies demonstrated the benefits of using Tissue-Doppler Echocardiography in the study of right ventricular function in

various diseases that affect the right ventricle (4, 25). In most of the studies in this field, the right ventricle function has been evaluated by tissue Doppler echocardiography (26); however, a study notes that myocardial performance index measured by tissue Doppler imaging (TDI-MPI) has been useful in assessing RV dysfunction in adults with PH (27). Ionescu et al., for the first time have reported the utility of Doppler echocardiography for the detection and monitoring of RV dysfunction (28). They indicated that the dysfunction is correlated with the severity of CF. Koestenberger and Ravekes noted that S' wave has significantly decreased in patients with CF in the right ventricle and is a good indicator for evaluating these patients (29). Sellers et al., demonstrated that patients with CF which had normal EF in conventional echocardiography had 50% abnormalities in echo strain in men and 100% abnormalities in echo strain rate in left ventricular evaluation that were not shown in conventional echo (21).

Baño-Rodrigo et al., examined the right heart function using Doppler echo and PFT in 37 patients with CF, indicating right ventricular dysfunction in these patients (30). Evaluation of the function of right ventricle in patients with CF, with Tissue-Doppler and strain rate echocardiography showed decrease of the function in these patients and suggest that these patients have less function in the heart when they appear healthy, while they had FEV1 about 91% in PFT. In literature review we found only one study which investigated both right and left ventricular function in CF and healthy children in a prospective cohort study. In a recent study, cardiac function of children with CF was compared with healthy children (18). The results of this study indicated that there were not significant differences regarding pulmonary function between studied groups. Results of TDE demonstrated

reduced right ventricular systolic function and lower strains of both right and left ventricles in children with CF than healthy ones. They concluded that children with CF had increased arterial stiffness, reduced right and left ventricular function during the early stages of the disease. Our results were similar to that reported by a later study especially regarding the similar pulmonary function of two studied groups. Such findings support the concept that in patients with CF, cardiac function could be influenced directly by CFTR gene dysfunction. Some in vivo studies indicated that CFTR regulates the cardiomyocyte contraction rate and could induce left ventricular dysfunction and aortic stiffness (reference). However, we could not ignore the potential role of pulmonary disease in cardiovascular system function. Moreover, CF related comorbidities such as diabetes, hypoxia and other disease could also influence on cardiovascular system.

4-1. Limitations of the study

The limitation of current study was the cross sectional design of the study, small sample size and shorter duration of follow up. It is recommended to plan further studies in this field for better understanding of the mechanism of cardiac impairment in CF patient.

5- CONCLUSION

The findings of this study indicated that there was some subclinical cardiac dysfunction in patients with CF during early stage of the disease which could not be diagnosed by routine echocardiography. Earlier detection of such impairments would be helpful for better management of the disease and preventing CF related complications and improving the quality of care as well as quality of life of CF patients. It is recommended to consider tissue Doppler echocardiography in the

earlier period of CF patients follow up program.

6- CONFLICT OF INTEREST: None.

7- ABBREVIATIONS

A: peak velocity during late diastole,

E: peak velocity during early diastole,

A': Annular peak velocity during late diastole,

E': Annular peak velocity during early diastole,

S': Annular peak velocity during systole,

DT: deceleration time, ms: millisecond,

MPI: Myocardial performance index, IVRT: isovolumetric relaxation time,

IVCT: isovolumetric contraction time,

LVEF: left ventricular ejection fraction,

LV-FS: left ventricular fractional shortening,

PEF: peak expiratory flow,

FEV1: forced expiratory volume in 1 s,

FVC: forced vital capacity,

FEV1/FVC: the ratio of FEV1 to FVC.

8- REFERENCES

1. Ghaderian M, Keikhaei B, Heidari M, Salehi Z, Malamiri RAJTJoTUHC. Tissue Doppler echocardiographic findings of left ventricle in children with sickle-cell anemia. 2012;7(3):106.
2. Rubin BK. Unmet needs in cystic fibrosis. Expert opinion on biological therapy. 2018;18(sup1):49-52.
3. Correale M, Totaro A, Ieva R, Brunetti ND, Di Biase MJI, medicine e. Time intervals and myocardial performance index by tissue Doppler imaging. 2011;6(5):393-402.
4. Kjærgaard J. Assessment of right ventricular systolic function by tissue Doppler echocardiography: Faculty of Health Sciences, University of Copenhagen; 2011.
5. Liu L, Jin X, Hu C-F, Zhang Y-P, Li R, Shen C-X. Amphiregulin enhances cardiac fibrosis and aggravates cardiac dysfunction in mice with experimental myocardial infarction partly through activating EGFR-dependent

- pathway. *Basic research in cardiology*. 2018;113(2):12.
6. Pallin M, Keating D, Kaye DM, Kotsimbos T, Wilson JW. Subclinical left ventricular dysfunction is influenced by genotype severity in patients with cystic fibrosis. *Clinical Medicine Insights: Circulatory, Respiratory and Pulmonary Medicine*. 2018;12:1179548418794154.
 7. G B-vM, MJ C, Kwakkel-van Erp JM NM, S T, HW DV, EA vdG. Pulmonary hypertension is a mild comorbidity in end-stage cystic fibrosis patients. *The Journal of Heart and Lung Transplantation*. 2013;32(6):609-14.
 8. Koestenberger M, Ravekes WJJoCF. Subclinical deterioration of systolic right ventricular function parameters in adolescents with mild cystic fibrosis. 2013;12(4):417.
 9. Ronai C, Ghelani SJ, Marshall AC, Harrild DM, Gauvreau K, Colan SD, et al. Characterization of Left Ventricular Dysfunction by Myocardial Strain in Critical Pulmonary Stenosis and Pulmonary Atresia After Neonatal Pulmonary Valve Balloon Dilatation. *The American journal of cardiology*. 2019;123(3):454-9.
 10. Luciani A, Villella VR, Esposito S, Brunetti-Pierri N, Medina DL, Settembre C, et al. Cystic fibrosis: a disorder with defective autophagy. 2011;7(1):104-6.
 11. Simanovsky N, Gileles-Hillel A, Frenkel R, Shosayov D, Hiller NJJoti. Correlation between computed tomography expression of pulmonary hypertension and severity of lung disease in cystic fibrosis patients. 2013;28(6):383-7.
 12. Tonelli ARJCoipm. Pulmonary hypertension survival effects and treatment options in cystic fibrosis. 2013;19(6):652.
 13. Ziegler B, Perin C, Casarotto FC, Fagondes SC, Menna-Barreto SS, Dalcin PdTRJTrj. Pulmonary hypertension as estimated by Doppler echocardiography in adolescent and adult patients with cystic fibrosis and their relationship with clinical, lung function and sleep findings. 2018;12(2):754-61.
 14. Hayes D, Daniels CJ, Kirkby S, Kopp BT, Nicholson KL, Nance AE, et al. Polysomnographic differences associated with pulmonary hypertension in patients with advanced lung disease due to cystic fibrosis. 2014;192(3):413-9.
 15. Ratjen FJTLRM. Pulmonary artery hypertension: an underrated disease manifestation in cystic fibrosis? 2016;4(8):596-8.
 16. Raghu G, Collard HR, Egan JJ, Martinez FJ, Behr J, Brown KK, et al. An official ATS/ERS/JRS/ALAT statement: idiopathic pulmonary fibrosis: evidence-based guidelines for diagnosis and management. 2011;183(6):788-824.
 17. Chung KF, Wenzel SE, Brozek JL, Bush A, Castro M, Sterk PJ, et al. International ERS/ATS guidelines on definition, evaluation and treatment of severe asthma. 2014;43(2):343-73.
 18. Kanar B, Ozben B, Yıldırım E, Ozmen İ, Aydın R. Right ventricular dyssynchrony and its improvements after pulmonary rehabilitation in patients with chronic obstructive pulmonary disease. *Echocardiography*. 2018;35(9):1335-41.
 19. Belle-van Meerkerk G, Cramer MJ, Kwakkel-van Erp JM, Nugroho MA, Tahri S, de Valk HW, et al. Pulmonary hypertension is a mild comorbidity in end-stage cystic fibrosis patients. *J Heart Lung Transplant*. 2013;32(6):609-14.
 20. Simanovsky N, Gileles-Hillel A, Frenkel R, Shosayov D, Hiller N. Correlation between computed tomography expression of pulmonary hypertension and severity of lung disease in cystic fibrosis patients. *J Thorac Imaging*. 2013 Nov;28(6):383-7.
 21. Sellers ZM, McGlocklin L, Brasch A. Strain rate echocardiography uncovers subclinical left ventricular dysfunction in cystic fibrosis. *J Cyst Fibros* 2015;14(5):654-60.
 22. Labombarda F, Saloux E, Brouard J, Bergot E, Milliez P. Heart involvement in cystic fibrosis: A specific cystic fibrosis-related myocardial changes? *Respiratory medicine*. 2016;118:31-8.

23. Wolf T, Anjorin A, Posselt H, Smaczny C, Vogl TJ, Abolmaali N. [MRI-based flow measurements in the main pulmonary artery to detect pulmonary arterial hypertension in patients with cystic fibrosis]. *Rofo*. 2009;181(2):139-46.
24. Sciatti E, Vizzardi E, Bonadei I, Valentini F, Menotti E, Prati F, et al. Focus on echocardiographic right ventricular strain analysis in cystic fibrosis adults without cardiovascular risk factors: a case-control study. *Internal and emergency medicine*. 2019;1-7.
25. Correale M, Totaro A, Ieva R, Brunetti ND, Di Biase M. Time intervals and myocardial performance index by tissue Doppler imaging. *Internal and emergency medicine*. 2011;6(5):393-402.
26. Ghandi Y, Sharifi M, Habibi D, Dorreh F, Hashemi M. Evaluation of left ventricular function in obese children without hypertension by a tissue Doppler imaging study. *Annals of pediatric cardiology*. 2018;11(1):28.
27. Friesen RM, Schäfer M, Burkett DA, Cassidy CJ, Ivy DD, Jone P-N. Right Ventricular Tissue Doppler Myocardial Performance Index in children with pulmonary hypertension: relation to invasive hemodynamics. *Pediatric cardiology*. 2018;39(1):98-104.
28. Ionescu AA, Ionescu A-A, Payne N, Obieta-Fresnedo I, FRASER AG, Shale DJA, et al. Subclinical right ventricular dysfunction in cystic fibrosis: a study using tissue Doppler echocardiography. 2001;163(5):1212-18.
29. Koestenberger M, Ravekes W. Subclinical deterioration of systolic right ventricular function parameters in adolescents with mild cystic fibrosis. *Journal of Cystic Fibrosis*. 2013;12(4):417.
30. Baño-Rodrigo A, Salcedo-Posadas A, Villa-Asensi JR, Tamariz-Martel A, Lopez-Neyra A, Blanco-Iglesias E. Right ventricular dysfunction in adolescents with mild cystic fibrosis. *Journal of Cystic Fibrosis*. 2012;11(4):274-80.