

## **Cri du Chat Syndrome: a Case Report with Recurrent Pneumonia and Chronic Stridor**

\*Nilay Ranjan Bagchi<sup>1</sup>, Susanta Bhanja<sup>2</sup>

<sup>1</sup> Associate Professor of Pediatrics, Medical College Hospital, Kolkata, India.

<sup>2</sup> RMO Cum clinical Tutor of Pediatrics, Medical College Hospital, Kolkata, India.

### ***Abstract***

#### ***Introduction***

Cri du chat syndrome is a rare genetic disorder due to deletion of variable length of short arm of chromosome 5(5p). It mainly presents with typical cat like cry, facial dysmorphism, poor growth with feeding problems and severe cognitive, speech, and motor delays.

#### ***Case Report***

We present here a one year old child who did not presented with typical features but presented with recurrent pneumonia with chronic stridor since early infancy. On evaluation we found short flabby epiglottis and we did karyotyping which showed 5P deletion syndrome.

#### ***Conclusion***

Cri du chat syndrome can be presented with atypical features like chronic stridor and recurrent pneumonia without having typical cat like cry. Early diagnosis is necessary for proper counselling of parents and treatment of the patient.

***Key Words:*** Chronic stridor, 5P deletion, Recurrent pneumonia.

---

#### ***\*Corresponding Author:***

Nilay Ranjan Bagchi, MD, Medical College Hospital, Kolkata, India.

Email: nrbagchiped@gmail.com

Received date: Sep 3, 2015 Accepted date: Sep 12, 2015

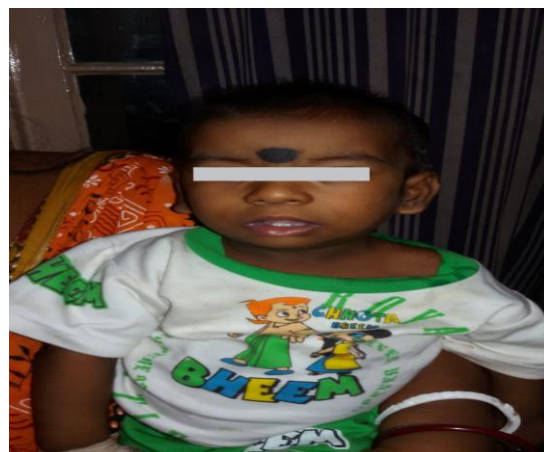## Introduction

Cri Du Chat syndrome is rare chromosomal abnormality characterized by deletion of variable length of short arm of chromosome 5. The condition affects an estimated 1 in 50,000 live births, strikes all ethnicities, and is more common in females with a ratio of 4: 3. This syndrome was first described by Jeune et al. (1). It usually presented with facial dysmorphism, typical cat like cry, severe psychomotor delay with cognitive dysfunction, speech delay, microcephaly with excessive drooling of saliva. Other common findings include hypotonia, growth retardation, hypertelorism, epicanthic folds, strabismus, flat nasal bridge, down turned mouth, micrognathia, low set ear, short figure, single palmer crease and congenital cardiac defects like ventricular septal defect, atrial septal defect, patent ductus arteriosus, tetralogy of fallot (2, 3).

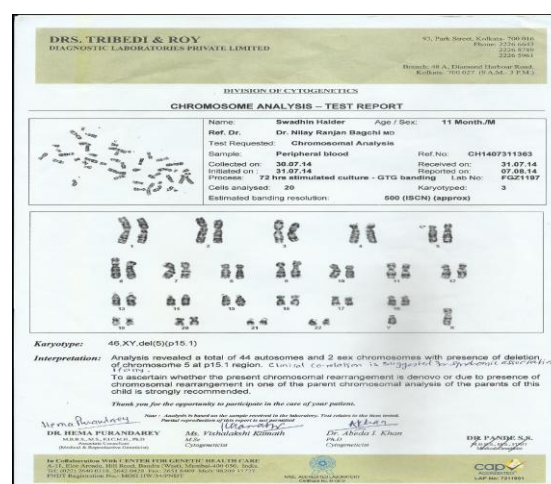
## Case Report

A one year boy presented chronic stridor from 7 days of life and recurrent pneumonia. His birth weight was 2 kg and born out of a non consanguineous marriage. There was no history of birth asphyxia. After through clinical examination there were few atypical facial features like down turned mouth, micrognathia, low set ears, microcephaly, flat nasal bridge with excessive drooling of saliva (Figure.1). There was mild psychomotor developmental delay. Organomegaly was not present. Congenital malformation of heart and lung was not detected. Skeletal surveys were normal and barium swallow study showed no trachea-oesophageal fistula. MRI of brain and echocardiography were normal. Immunodeficiency status was evaluated and found no abnormality. In the throat examination we found there was small flabby epiglottis and laryngomalecia was

ruled out. After excluding all the common possibilities we did a karyotyping and there was deletion of a part of chromosome 5 (Figure.2).



**Fig 1:** Atypical Facial Features



**Fig 2:** Karyotyping of the Patient

## Discussion

The patient presented with atypical clinical features of cri du chat syndrome. The typical high pitched cat like cry was not present in this case. Instead of being presented with chronic stridor from 7 days of life and recurrent pneumonia which confused us from suspecting cri du chat syndrome initially. Stridor is a high-pitched sound resulting from turbulent air flow that occurs due to persistent upper airway obstruction. When the stridor is above the glottis it causes inspiratory

stridor. Most common cause of chronic stridor is laryngomalacia (4, 5).

Recurrent lower respiratory infection is defined as having two or more episode of pneumonic attack in a single year or three or more attacks in any period of time. Recurrent lower respiratory infection can occur due to congenital anomalies of heart and lung, impaired airway secretion clearance, aspiration syndrome, allergic and immunological abnormalities(6).

Inspiratory stridor may be present in cri du chat syndrome since birth due to anomalies of larynx (small, narrow, diamond shaped) and of the epiglottis (flabby, small, hypotonic) as well as to neurological and functional alterations (7, 8). Recurrent pneumonia in this case is due to recurrent aspiration as the reflex mechanism of larynx to close and open is not properly developed (6, 9)

### Conclusion

Cri du chat syndrome can be presented with atypical features like chronic stridor and recurrent pneumonia without having typical cat like cry. Early diagnosis is necessary for proper counselling of parents and treatment of the patient.

### Acknowledgment

Authors thank the authorities of Medical College Hospital, Kolkata-India for allowing us to report the case.

**Conflict of interest:** None.

### Authors Contributions

Both authors contributed together in patient evaluation, doing investigations, data compiling and cross checking references. Both authors read and approved the final manuscript.

### References

1. Lejeune J, Lafourcade J, Berger R, Vialatte J, Boeswillwald M, Seringe P, et al. Trois cas de délétion partielle du bras court d'un chromosome 5. *CR Acad Sci [D](paris)* 1963; 257:3098-02
2. Overhauser J, Huang X, Gersh M, Wilson W, McMahon J, Bengtsson U, et al. Molecular and phenotypic mapping of the short arm of chromosome 5: sublocalization of the critical region for the cri-du-chat syndrome. *Hum Mol Genet* 1994; 3(2):247-52.
3. Maria Rosa Pizzamiglio , Cristino Volpe , Laura Piccardi. A longitudinal study in atypical Cri-du chat profile: A single case report. *Case Reports in Clinical Medicine* 2013; 2(2):100-7.
4. Leung AK, Cho HY. Diagnosis of stridor in children. *Am Fam Physician* 1999; 60(8):2289-96.
5. Cotton RT, Reilly JS. Stridor and airway obstruction. In: Bluestone C, Stool S, Kenna M (eds). *Pediatric Otolaryngology*. 3<sup>rd</sup> Ed. Philadelphia: WB Saunders Company; 1995. p.1275-88.
6. Panitch HB. Evaluation of recurrent pneumonia. *Pediatr Infect Dis J* 2005; 24(3):265-66.
7. Duarte AC, Cunha E, Roth JM, Ferriera FL, Garcias GL, Martino-Roth MG. Cytogenetics of genetic counseling patients in Pelotas, Rio Grande do Sul, Brazil. *Genet Mol Res* 2004; 3(3):303-8.
8. Navee Kaur. Cri-du-Chat Syndrome. Available at: <http://ghr.nlm.nih.gov/condition/cri-du-chat-syndrome>>U.S. National Library of Medicine, University of Maryland Medical Center. Accessed in 23 July 2015.
9. Şit Uçar, Başak Adakl, Binnaz Çelik, Özlem Özgür, Gülseren Şahin, Gürses Şahin, et al. Evaluation of Etiology in Infants with Recurrent Pneumonia and Chronic Stridor in Turk Thorac J 2014;15(3): 122-7