

Mastoiditis, Bezold Abscess, Dural Sinus Thrombosis, and Bilateral Abducens Nerve Palsy in a Child with Chronic Suppurative Otitis Media: A Rare Case Report

Suresh Kumar Angurana¹, *Arun Bansal¹, Ankit Mehta¹, Sandeep Bansal², Muralidharan Jayashree¹

¹Department and institute, Department of Pediatrics, Post Graduate Institute of Medical Education and Research (PGIMER), Chandigarh, India, 160012.

²Departement of Otorhinolaryngology, Post Graduate Institute of Medical Education and Research (PGIMER), Chandigarh, India, 160012.

Abstract

Chronic suppurative otitis media (CSOM) is a common childhood infectious disease in developing countries. It may be associated with various life threatening intra-cranial or extra-cranial complications. We report a 10 year-male child with a rare combination of right sided unsafe CSOM, mastoiditis, Bezold abscess, sigmoid and transverse sinus thrombosis, and bilateral abducens nerve palsy and he was successfully treated with antibiotics, surgery, and anticoagulation. The combination of CSOM with mastoiditis, Bezold abscess, sigmoid and transverse sinus thrombosis, and bilateral abducens nerve palsy is rare. Aggressive management with prompt antibiotic therapy, surgery, and anticoagulation can lead to favorable outcome.

Key Words: Abducens nerve palsy, Bezold abscess, Child, Chronic suppurative otitis media, Mastoiditis.

*Please cite this article as: Angurana SK, Bansal A, Mehta A, Bansal S, Jayashree M. Mastoiditis, Bezold Abscess, Dural Sinus Thrombosis, and Bilateral Abducens Nerve Palsy in a Child with Chronic Suppurative Otitis Media: A Rare Case Report. Int J Pediatr 2019; 7(2): 9049-52. DOI: **10.22038/ijp.2018.33617.2969**

*Corresponding Author:

Dr. Arun Bansal, Professor, Department of Pediatrics, Advanced Pediatric Center, Postgraduate Institute of Medical Education and Research, Chandigarh, India, 160012.

Email: drarunbansal@gmail.com

Received date: Jul.11, 2018; Accepted date: Oct. 22, 2018

1- INTRODUCTION

Chronic suppurative otitis media (CSOM) is a notorious infection in developing countries (1, 2). In tubotympanic (safe or benign) type, pars tensa of tympanic membrane (TM) is involved and have no serious complications whereas, in atticointral (unsafe or dangerous) type, pars flaccida is involved and is associated with various life-threatening complications (2, 3). It may be associated with intra-temporal, intra-cranial or extra-cranial complications. Spread of infection lead to mastoiditis/mastoid abscess and cranial nerve paralysis. Bezold abscess is a complication of acute mastoiditis when the disease passes inferiorly through the medial aspect of the mastoid tip into the sheath of the sternocleidomastoid muscle (2, 4, 5). We report successful management of a rare combination of right sided unsafe CSOM, mastoiditis, Bezold abscess, sigmoid and transverse sinus thrombosis, and bilateral abducens nerve palsy.

2- CASE REPORTS

A 10-year boy presented with purulent right ear discharge, fever (103 F, intermittent), vomiting, gradually increasing painful right neck swelling, and limitation of neck movements for 5 days. He had intermittent episodes of purulent right ear discharge since last 3 years for which he used to be treated with oral antibiotics on an out-patient basis in a local hospital. He was 4th in birth order and his parents and 3 elder female siblings were normal. Examination revealed a 5x6 cm erythematous, tender and fluctuant swelling over right side of neck extending from mastoid to the level of cricoid cartilage. There was pus in right ear. The tympanic membrane (TM) showed a central perforation with cholesteatoma flakes in the middle ear with destruction of

the posterior malleolar fold and attic. Neurologically, he had Glasgow Coma Scale of 13/15, bilateral abducens nerve palsy (**Figure 1a**), and bilateral papilledema. Other systemic examination was normal. Investigations revealed hemoglobin of 8.6 gm/dL, Total leukocyte Count (TLC) 16,900/cumm, platelets 17,000/cumm, CRP 232 mg/dL, normal coagulation profile, liver and renal functions, and non-reactive human immunodeficiency virus (HIV) enzyme linked immunosorbent assay (ELISA). Computerized tomography of temporal bone and neck revealed heterogenous density material filling right mastoid cells; erosion of middle ear ossicles, bony septa, posterolateral wall of mastoid, and inferior part of mastoid in the region of digastric ridge (**Figure 1b**), and an abscess in relation to right sternocleidomastoid muscle extending from tip of mastoid to the level of 4th cervical vertebra (**Figure 1c** and **1d**).

Magnetic resonance imaging (MRI) brain revealed thrombus in right transverse and sigmoid sinus. He was diagnosed to have right sided unsafe CSOM with complications as mastoiditis, Bezold abscess, sigmoid and transverse sinus thrombosis, and bilateral sixth nerve palsy. Incision and drainage of Bezold abscess was done and 20 ml pus drained. Blood and pus culture yielded *Proteus mirabilis*. Right canal wall down mastoidectomy showed cholesteatoma filling whole of right middle ear, attic and mastoid antrum and it extended into sigmoid sinus eroding the sinus plate and all ossicles in middle ear. He was treated with appropriate intravenous antibiotics for four weeks and anticoagulation (subcutaneous enoxaparin followed by warfarin) for three months. There was significant improvement in fever and ear discharge by day 8. Six months after follow-up, there was improvement in sixth cranial nerve palsy.

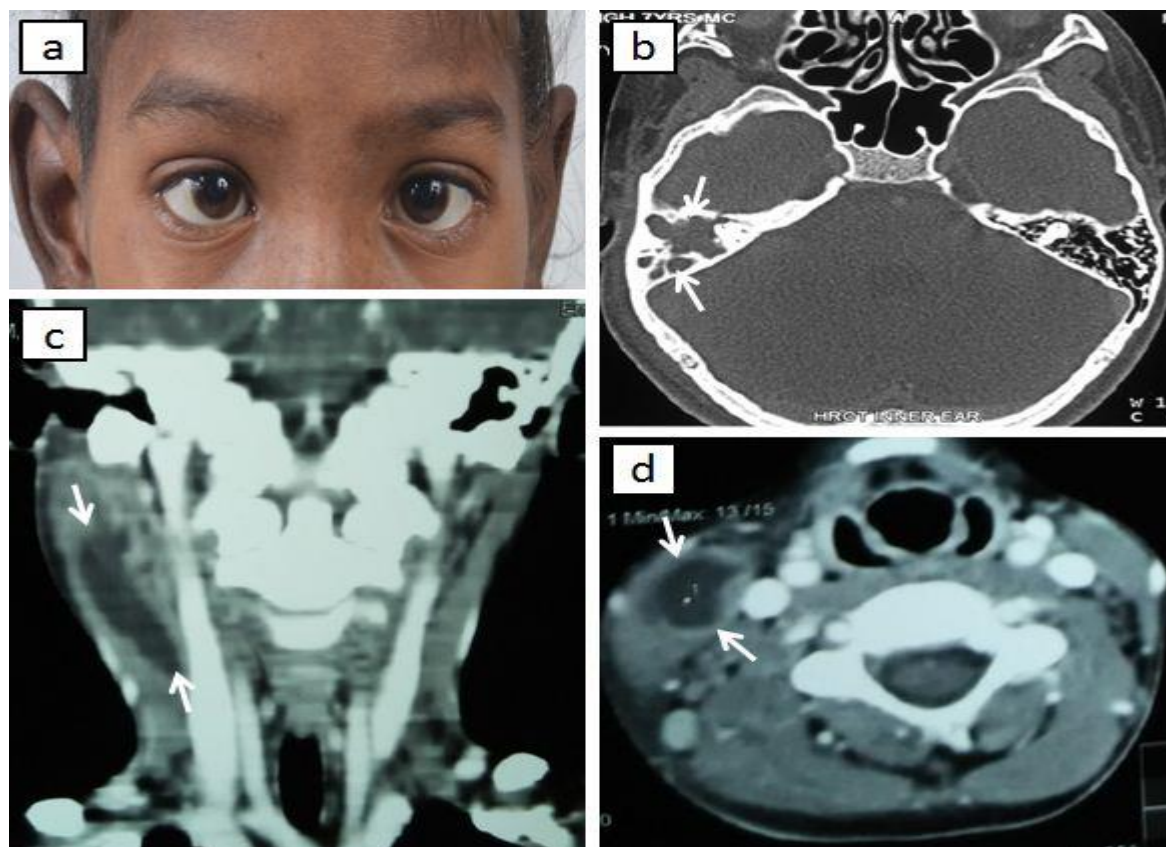


Fig.1 (a): Clinical photograph showing bilateral lateral rectus palsy; (b) HRCT of temporal bones showing right mastoid cells filled with heterogenous density material suggestive of mastoiditis (c and d). CECT neck revealed abscess in relation to right sternocleidomastoid muscle extending from tip of mastoid to the level of 4th cervical vertebra.

3- DISCUSSION

Atticoantral CSOM is associated with various life threatening intracranial (IC), and Extracranial (EC) complications due to spread of infection to contiguous structures (1, 2, 5-8). Bezold abscess is a rare complication of mastoiditis (following acute otitis media (AOM), or CSOM) in post-antibiotic era, occurring in 2/1000-100,000 cases (7). Middle ear and mastoid infection can cause dural venous sinus thrombosis either by direct spread of infection or via the emissary veins. Dural sinus thrombosis can lead to raised intracranial pressure (ICP) due to obstruction to venous outflow and venous engorgement, and impaired CSF reabsorption (9, 10). Sharma et al. (9) conducted a study involving 45 cases of CSOM with complications, and noted that

20 cases had EC, while 25 cases had IC complications. The common EC complications were subperiosteal abscess (20%), labyrinthitis (17.7%), and facial nerve palsy (15.5%); and common IC complications were brain abscess (29%), meningitis (13%), and lateral sinus thrombophlebitis (11%). In a retrospective study involving 4,630 cases with CSOM, Yorgancilar et al. (11) noted that 121 (2.6%) cases had complications and among them 47.1% (n=57) had EC, 30.6% (n=37) had IC, and 22.3% (n=27) had multiple combined complications. The common EC complications noted in this study were mastoid abscess (28.3%), labyrinthitis (9%), facial nerve paralysis (8.4%), and Bezold's abscess (1.3%); and IC complications were lateral sinus thrombophlebitis (19.5%), perisigmoid sinus abscess (13.5%), meningitis (9%),

brain abscess (6.5%), and extradural abscess (4.5%). As an intracranial complication of CSOM, abducens nerve is commonly affected as it emerges nearest to skull base, has longest course, and least protected by dural covering. When it passes adjacent to mastoid, spread of infection and inflammation to meninges lead to its palsy. Moreover, compression of nerve against petroclinoid ligament, interruption of its fragile blood supply, petrous apicitis, and inferior petrosal sinus thrombosis also cause abducens nerve palsy (12, 13). In CSOM, occurrence of bilateral abducens nerve palsy is rarely reported in literature as compared to unilateral involvement. Lang et al. (12) reported a 14-year girl with bilateral abducens palsy as the initial symptom of sinus vein thrombosis after mastoiditis who recovered rapidly following mastoidectomy, antibiotics, and heparin therapy. Balasubramanian et al. (13) reported 18-year boy with extensive dural sinus thrombosis and bilateral lateral rectus palsy who was managed with antibiotics and heparin. This is the first reported case of a rare combination of mastoiditis, Bezold abscess, sigmoid and transverse sinus thrombosis, and bilateral abducens nerve palsy as complications of CSOM.

4- CONCLUSION

CSOM can lead to various life-threatening complications. Outcome is favorable with prompt antibiotic therapy, surgery, and anticoagulation.

5- CONFLICT OF INTEREST: None.

6- REFERENCES

1. Verhoeff M, van der Veen EL, Rovers MM, Sanders EA, Schilder AG. Chronic suppurative otitis media: a review. *Inter J Pediatr Otorhinolaryng.* 2006; 70(1): 1-12.
2. Prakash R, Juyal D, Negi V, Pal S, Adekhandi S, Sharma M, Sharma N. Microbiology of chronic suppurative otitis media in a tertiary care setup of uttarakhand state, India. *N Am J Med Sc.* 2013; 5(4): 282-87.
3. Acuin J. Chronic suppurative otitis media. *Clin Evid.* 2004: 710-29.
4. Berman S. Otitis media in developing countries. *Pediatrics.* 1995; 96(1 Pt 1): 126-31.
5. Wahid FI, Khan A, Khan IA. Complications of chronic suppurative otitis media: challenge for a developing country. *Kulak Burun Bogaz Ihtis Derg.* 2014; 24(5): 265-70.
6. Mittal R, Lisi CV, Gerring R, Mittal J, Mathee K, Narasimhan G, et al. Current concepts in the pathogenesis and treatment of chronic suppurative otitis media. *J Med Microbiol.* 2015; 64(10): 1103-16.
7. Nelson D, Jeanmonod R. Bezold abscess: a rare complication of mastoiditis. *Am J Emerg Med.* 2013; 31(11): 1626 e3-4.
8. Pradhananga R. An unusual complication of chronic suppurative otitis media: bezold abscess progressing to scapular abscess. *International archives of otorhinolaryngology.* 2014;18(4):412-4.
9. Sharma N, Jaiswal AA, Banerjee PK, Garg AK. Complications of Chronic Suppurative Otitis Media and Their Management: A Single Institution 12 Years' Experience. *Indian J Otolaryngol Head Neck Surg.* 2015; 67(4): 353-60.
10. Singh GB, Rai AK, Singh S, Sahu R, Arora R. Management of otogenic lateral sinus thrombosis. *Auris Nasus Larynx.* 2014; 41(2): 143-47.
11. Yorgancılar E, Yildirim M, Gun R, Bakir S, Tekin R, Gocmez C, et al. Complications of chronic suppurative otitis media: a retrospective review. *Eur Arch Otorhinolaryngol.* 2013; 270(1): 69-76.
12. Lang M, Schmidbauer J, Voges M, Kasmann-Kellner B, Heinemann-Vernaleken B, Ruprecht KW. Mono- or bilateral abducens paralysis as the initial symptom of sinus vein thrombosis. *Ophthalmologie.* 2002; 99(1): 49-52. [Article in German].
13. Balasubramanian A, Mohamad I, Sidek D. Extensive dural sinus thrombosis and bilateral lateral rectus palsy as an uncommon complication of chronic suppurative otitis media. *BMJ Case Rep.* 2013. doi: 10.1136/bcr-2012-007414.