

## Management of Biloma due to Biliary Tract Injury after Laparoscopic Cholecystectomy in a patient with Atypical Anatomy: A Case Report

Ahmad Mohammadipour<sup>1</sup>, Shiva Ghaderifar<sup>2</sup>, Marjan Joodi<sup>1</sup>, Saeedeh Majidi<sup>3</sup>, \*Mohammad Mahdi Khazravi<sup>3</sup>

<sup>1</sup>Department of Pediatric Surgery, Mashhad University of Medical Sciences, Mashhad, Iran.

<sup>2</sup>Master of Science in Environmental Health Engineering, Mashhad University of Medical Sciences, Mashhad, Iran.

<sup>3</sup>Fellowship of Pediatric Surgery, Mashhad University of Medical Sciences, Mashhad, Iran.

### Abstract

**Introduction:** Biliary tract injury is a major complication of laparoscopic cholecystectomy which can be very challenging. But, the important part is to know the accurate anatomy of the ducts and site of the injury before any surgical attempt for ligation or repair. In this case a disaster might happen if we do not consider biliary anatomical abnormality as the main issue.

### Case Report

In this case, there was an additional duct originating from the right hepatic lobe and inserting directly to the common bile duct (CBD) along with the right hepatic duct. The injury to this branch led to biloma secretion from two tearing sites, one proximal to the branch and another distal of the branch adjacent to CBD, during laparoscopic cholecystectomy.

### Conclusion

There are numerous anatomic variations in the biliary tract, so according to this case we highly recommend to assay the exact anatomy before any intervention by means of Magnetic resonance cholangiopancreatography (MRCP) or intraoperative cholangiography.

**Key Words:** Anatomical Abnormality, Biliary tract injury, Child, Laparoscopic cholecystectomy.

\*Please cite this article as: Mohammadipour A, Ghaderifar Sh, Joodi M, Majidi S, Khazravi MM. Management of Biloma due to Biliary Tract Injury after Laparoscopic Cholecystectomy in a patient with Atypical Anatomy: A Case Report. Int J Pediatr 2019; 7(8): 9799-9802. DOI: [10.22038/ijp.2019.39693.3380](https://doi.org/10.22038/ijp.2019.39693.3380)

---

### \*Corresponding Author:

Mohammad Mahdi Khazravi, Department of Pediatric Surgery, Mashhad University of Medical Sciences, Mashhad, Iran.

Email: [khazravimm961@mums.ac.ir](mailto:khazravimm961@mums.ac.ir)

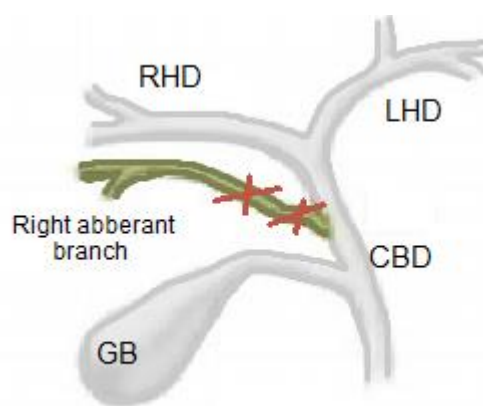
Received date: Jan.20, 2019; Accepted date: Jun.22, 2019

## 1- INTRODUCTION

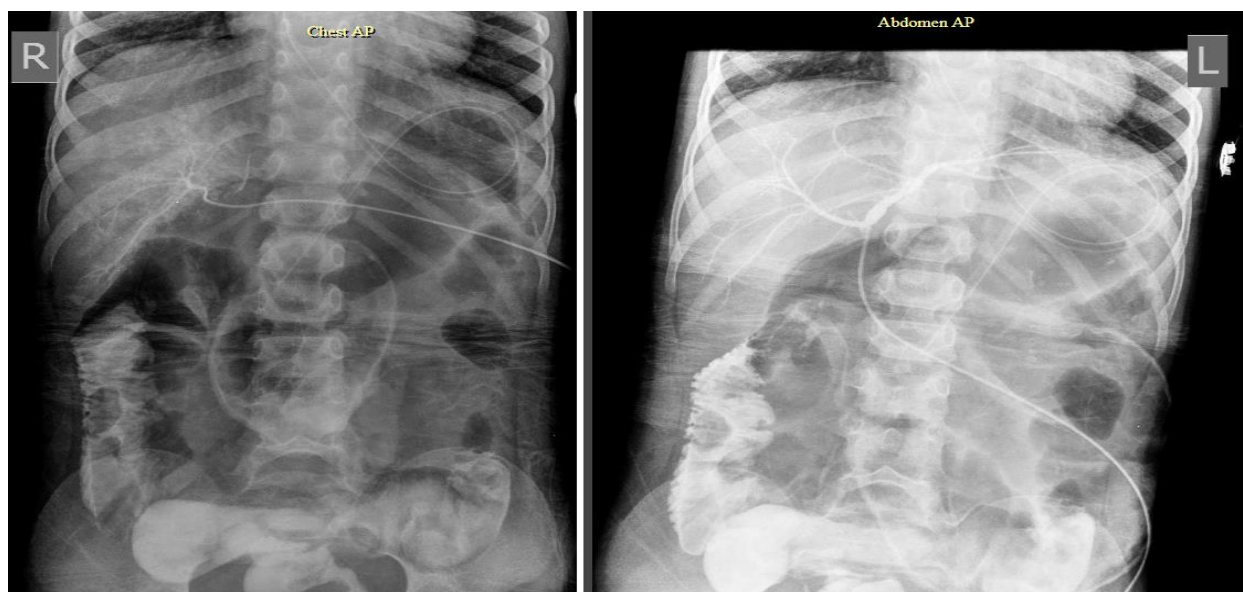Laparoscopic cholecystectomy (LC) has been the most commonly performed operation for the gallstones for 15 years (1). LC was introduced after the development of the laparoscopic procedures and became a replacement of open cholecystectomy (OC) over time (2). The advantages of LC compared to OC are shorter hospitalization time and recovery, and less postoperative pain (3). However, there are some complications after LC. Biliary tract injury (BTI) is a major complication of LC which can be challenging and has substantial consequences for surgeons and patients (4, 5). Some factors that cause BTI are: inexperience in identification of anatomy, lack of recognition of the injuries during occurrence, acute cholecystitis, and bleeding. Some recommend routine surgical cholangiography to avoid the bile duct trauma or injuries. It also can indicate unusual anatomy (6). The clear illustration of cholangiography permits surgeons to have an accurate and immediate diagnosis of injuries by observing biliary tree and its variants (7). Correct diagnosis and management of biliary tract injuries are essential to prevent serious complications that need further reoperation (2). In the present study we aimed to report a case with biliary injury due to a rare anatomical variation.

## 2- CASE REPORT

A 4-year-old girl underwent laparoscopic cholecystectomy due to gallstone. Three days after the surgery, patient became icteric and complained of persistent pain, investigation of the cause revealed fluid accumulation around the liver. So the patient was referred to the Pediatric Surgery Center in Akbar hospital, Mashhad, Iran with suspicion of biliary tract trauma. Surgery exploration was done and bile secretion through two orifices was observed. The first one was close to the bed of gallbladder and the second one was adjacent to the CBD (**Figure.1**). Cholangiography through each orifice was done during surgery to investigate biliary tree anatomy and it was determined this traumatic duct was an anatomical variant branch along with the right hepatic duct (**Figure.2**). The proximal orifice was the connection site of this extra branch to the CBD and the distal orifice was the continuation of duct to the liver parenchymal. Ligation of the duct was done, proximally and distally. An intra-peritoneal drain was embedded. Liver enzyme, bilirubin and sonographic results were normal in the short-term follow-up. The patient was discharged with a good general condition, and there was no specific issue in the one-month follow-up.



**Fig.1:** Schematic image of injured extra right hepatic branch.



**Fig.2:** Cholangiography during the reoperation.

### 3- DISCUSSION

Biliary tract injuries occurring during laparoscopic cholecystectomy may cause disability or mortality after a curative procedure. Various technical procedures can be used to prevent BTI during LC, especially precise dissection to recognize Calots triangle (8). A useful treatment method with low morbidity is intraoperative repair of BTI, but this is rarely done because the diagnosis of BTI is usually done after operation (9). One of the causes of BTI is associated with anatomical variations (10). In the current case the patient had an unusual biliary tract anatomy. There was an additional duct originating from the right hepatic lobe and inserting directly to the CBD along with the right hepatic duct. The biliary anatomical abnormalities occur in 18-39% of cases that are predisposed to biliary tract injuries in 3-6%. The abnormality of right hepatic ducts is one of the most dangerous anomalies (5). An additional and improper right hepatic biliary duct discharging into the common hepatic duct or cystic duct is observed in 7.4% of cases (11). Our case also had this anomaly. Awareness of anatomical variations and biliary tree anomalies is highly important

for the surgeons, failure to recognize them may have fetal complications, and this is the cause of most mistakes in the gallbladder surgery. So success in the laparoscopic cholecystectomy depends on such awareness (12). The ability of distinction of anomalies and normal variants can decrease diagnostic mistakes, help in surgical procedures, and avoid unwanted ductal injury especially at laparoscopic cholecystectomy (11). We highly recommend intra operative cholangiography as a useful means prior to any further intervention for ligation or even repair in the injured ducts (13). Considering this case, if cholangiography had not been done, any attempt to repair might have led to biliary stricture or cholangitis or biliary stasis resulting from inappropriate intervention.

### 4- CONCLUSION

There are numerous anatomic variations in the biliary tract, so according to this case we highly recommend to assay the exact anatomy before any intervention. By means of MRCP, or intraoperative cholangiography.

**5- CONFLICT OF INTEREST:** None.

## 6- REFERENCES

1. Zehetner J, Shamiyeh A, Wayand W. Lost gallstones in laparoscopic cholecystectomy: all possible complications. *The American Journal of Surgery*. 2007;193(1):73-8.
2. Sicklick JK, Camp MS, Lillemoe KD, Melton GB, Yeo CJ, Campbell KA, et al. Surgical management of bile duct injuries sustained during laparoscopic cholecystectomy: perioperative results in 200 patients. *Annals of Surgery*. 2005;241(5):786.
3. Savader SJ, Lillemoe KD, Prescott CA, Winick AB, Venbrux AC, Lund GB, et al. Laparoscopic cholecystectomy-related bile duct injuries: a health and financial disaster. *Annals of surgery*. 1997;225(3):268.
4. Barrett M, Asbun HJ, Chien H-L, Brunt LM, Telem DA. Bile duct injury and morbidity following cholecystectomy: a need for improvement. *Surgical endoscopy*. 2018;32(4):1683-88.
5. Parmeggiani D, Cimmino G, Cerbone D, Avenia N, Ruggero R, Gubitosi A, et al. Biliary tract injuries during laparoscopic cholecystectomy: three case reports and literature review. *Il Giornale di chirurgia*. 2010;31(1/2):16-9.
6. Archer SB, Brown DW, Smith CD, Branum GD, Hunter JG. Bile duct injury during laparoscopic cholecystectomy: results of a national survey. *Annals of surgery*. 2001;234(4):549.
7. Nuzzo G, Giuliante F, Giovannini I, Ardito F, D'Acapito F, Vellone M, et al. Bile duct injury during laparoscopic cholecystectomy: results of an Italian national survey on 56 591 cholecystectomies. *Archives of Surgery*. 2005;140(10):986-92.
8. Pesce A, Palmucci S, La Greca G, Puleo S. Iatrogenic bile duct injury: impact and management challenges. *Clinical and Experimental Gastroenterology*. 2019;12:121.
9. Alvarez F, De Santibañes M, Palavecino M, Sánchez Clariá R, Mazza O, Arbues G, et al. Impact of routine intraoperative cholangiography during laparoscopic cholecystectomy on bile duct injury. *British Journal of Surgery*. 2014;101(6):677-84.
10. Krähenbühl L, Sclabas G, Wente MN, Schäfer M, Schlumpf R, Büchler MW. Incidence, risk factors, and prevention of biliary tract injuries during laparoscopic cholecystectomy in Switzerland. *World journal of surgery*. 2001;25(10):1325-30.
11. Mathew DL, Kattakayam AT. Magnetic Resonance Cholangiopancreatography Evaluation of Gall Stone Disease in Pre-Operative Period and Correlation with Operative Findings. *Journal of Medical Research and Practice*. 2017;6(7):223-34.
12. Ibingira C. Gross Anatomical Variations and Congenital Anomalies of Surgical Importance in Hepatobiliary Surgery in Uganda. *East and Central African Journal of Surgery*. 2007;12(1):93-8.
13. Altieri MS, Yang J, Obeid N, Zhu C, Talamini M, Pryor A. Increasing bile duct injury and decreasing utilization of intraoperative cholangiogram and common bile duct exploration over 14 years: An analysis of outcomes in New York State. *Surgical endoscopy*. 2018;32(2):667-74.