

## **Aspergillus Fumigatus Endocarditis after Total Correction of Tetralogy of Fallot**

Mohammad Mahdavi<sup>1</sup>, \*Feisal Rahimpour<sup>2</sup>, Mahmood Hosseinzadeh Maleki<sup>3</sup>

<sup>1</sup>Department of Pediatric Cardiology, Rajaie Cardiovascular Medical and Research Center, Iran University of Medical Sciences, Tehran, Iran.

<sup>2</sup>Department of Cardiology, Imam Reza Hospital, Mashhad University of Medical Sciences, Mashhad, Iran.

<sup>3</sup>Department of Cardiac Surgery, Imam Reza Hospital, Mashhad University of Medical Sciences, Mashhad, Iran.

### **Abstract**

There are few studies about post-cardiac surgery fungal infections especially by *Aspergillus fumigatus*. In this paper we report a case of *Aspergillus fumigatus* endocarditis after tetralogy of Fallot total correction (TFTC), and permanent pacemaker (PPM) implantation. A five-year-old female patient with current history of total correction of tetralogy of fallot was admitted in Rajaie Cardiovascular Medical and Research Center, Tehran, Iran, with unexplained prolonged fever.

The fungal endocarditis was suspected. After three weeks' antifungal regimen, the fever was suppressed gradually and general condition was good. Current paper revealed the importance of clinical suspicion by physicians in pediatric cases with current history of cardiothoracic surgeries for prompt diagnosis and successful treatment of *Aspergillus fumigatus* endocarditis.

**Key Words:** *Aspergillus fumigatus*, Endocarditis, Galactomannan, Tetralogy of Fallot.

\*Please cite this article as: Mahdavi M, Rahimpour F, Hosseinzadeh Maleki M. *Aspergillus Fumigatus* Endocarditis after Total Correction of Tetralogy of Fallot. *Int J Pediatr* 2019; 7(12): 10605-609. DOI: **10.22038/ijp.2019.41338.3488**

---

### **\*Corresponding Author:**

Feisal Rahimpour (MD), Department of Pediatrics, Imam Reza Hospital, Pediatric Cardiology, Mashhad University of Medical Sciences, Mashhad, Iran.

Email: feisalahimpour@gmail.com AND Rahimpourf1@mums.ac.ir

Received date: Mar.14, 2019; Accepted date: Nov.22, 2019

## 1- INTRODUCTION

Fungal endocarditis is a rare infectious complication of patients undergoing heart surgery and is usually seen in immunosuppressed patients (1). Among the main contributing pathogens is *Aspergillus fumigatus* (2). There are few case presentations about post-cardiac surgery fungal infections especially by *Aspergillus fumigatus* in pediatric setting (3, 4). In this paper we report a case of *Aspergillus fumigatus* endocarditis after tetralogy of Fallot total correction (TFTC) and permanent pacemaker (PPM) implantation.

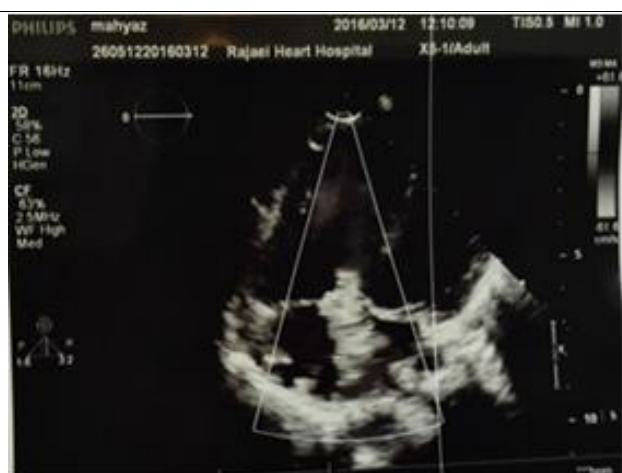## 2- CASE REPORTS

A five-year-old female patient with current history of total correction of tetralogy of fallot (two years ago) was admitted in Rajaie Cardiovascular Medical

and Research Center, Iran University of Medical Sciences, Tehran, Iran in January 2016. Her complaint was unexplained prolonged fever, vomiting, loss of appetite and headache. The patient was admitted for fever of unknown origin (FUO) assessment. The laboratory data results showed: leukocyte count 10,000 per mm<sup>3</sup>, hemoglobin 9.8, platelet count 279,000 per mm<sup>3</sup>, erythrocyte sedimentation rate (ESR) 80 mm per hour, C-Reactive Protein (CRP)= 161, and Procalcitonin= 4.80. She had no neutropenia. Salmonella typhi Ag and Wright test were negative and D-Dimer was 3062. Echocardiography showed abnormal thickness of VSD (ventricular septal defect) patch with heterogeneous echo-density and increased echo-density around pace wire (**Figure.1**).

**Fig.1:** Echocardiography in 4 chamber view showed abnormal thickness of VSD patch with heterogeneous echo-density and increased echo-density around pace wire.

VSD: ventricular septal defect.



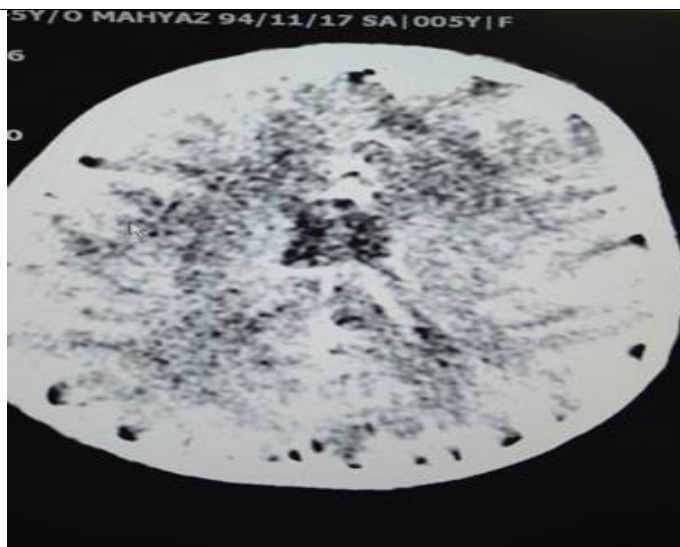The drug treatment for bacterial endocarditis was started but the fever did not respond. For evaluation of headache, the multi-slice spiral CT scan of the brain was done and small hyper-dense area in the left cortical region was seen. The CT-angiography revealed a saccular aneurysm measured 4.3\*3.9 mm with a connecting neck to middle cerebral artery measured 1.4 mm (**Figure.2**).

Ultrasonography of abdomen and pelvis was normal. The fever continued and as another differential diagnosis, the fungal endocarditis was suspected. For this matter, the Galactomannan was checked. Galactomannan was 1.9 higher than normal cut-off point of 0.5. Amphotericin B (liposomal) was started and regarding the protracted fever that did not respond to antibiotic and antifungal therapy, the

patient underwent open surgery for drainage of inter-ventricular septal abscess, extraction of endocardial pace, VSD path repair, and insertion of permanent epicardial pacemaker. Also, drainage of inter-ventricular septal abscess and ventricular septal defect repair were performed (**Figure.3**). The blood polymerase-chain reaction was positive for *Aspergillus fumigates* and medications

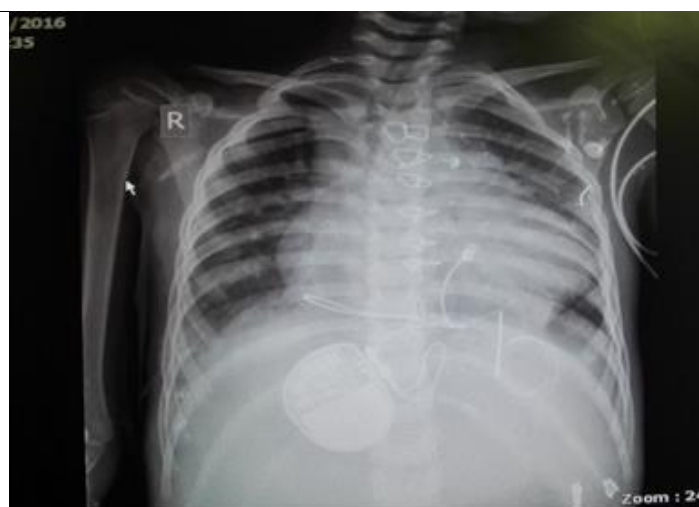
were changed to voriconazole and caspofungin. These were prescribed for more than three weeks but three weeks after this antifungal regimen, the fever was suppressed gradually and general condition was good. ESR and CRP became normal. Blood culture for *Aspergillus fumigates* became negative and Galactomannan decreased to normal level of 0.2.

**Fig.2:** Multi-slice spiral CT scan of the brain showed small hyper-dense area in the left cortical region.



**Fig.3:** CXR showed insertion of permanent epicardial pacemaker.

CXR: Chest X-ray.



### 3- DISCUSSION

In this paper we reported the first case of *Aspergillus fumigatus* endocarditis in our center in a developing country. These infections would usually have poor outcome despite prompt appropriate medical and surgical treatments; but our patient had complete improvement without adverse effects. Infective endocarditis has high rate of morbidity and mortality. The incidence of pediatric infective endocarditis is 0.05 to 0.12 cases per 100,000 per year (5, 6).

The patients may acquire *Aspergillus fumigatus* endocarditis during a heart surgery when operating-room air or CPB equipment is contaminated. Fungal endocarditis generally presents as large vegetations with possible systemic embolization, especially on prosthetic valves (2). But in presented pediatric case, there were atypical symptoms which were previously reported in some patients (7).

The common risk factors for *Aspergillus fumigatus* endocarditis include cardiothoracic surgery, anatomical cardiac abnormalities, intravenous drug use, prior antibiotic therapy, use of indwelling vascular catheters and other invasive monitoring devices, prolonged hospitalization and immunosuppression (8, 9). Surgical or medical procedure is the main predisposing factor of fungal endocarditis in one out of eight patients under cardiothoracic operations (4). *Aspergillus* does not grow well in standard blood culture media or fungal blood culture media (7, 10). However, the galactomannan was used in our study for both diagnosis and monitoring of therapeutic response; there is not sufficient data in pediatrics to use Galactomannan testing as a metric for disease response. Regarding high mortality rate of *Aspergillus* endocarditis, it is usually diagnosed in postmortem analysis (1, 2, 10); and diagnosis in live subjects is a bothersome issue.

As mentioned, there are few pediatric cases of *Aspergillus fumigatus* endocarditis after cardiac surgery. In a study in 1981 by Barst et al. (11) *Aspergillus fumigatus* endocarditis was reported in a 2 and a half -year-old girl after repair of tetralogy of fallot. Their reported case had fever and embolic phenomenon, including neurological symptoms as presenting manifestations. A 4-year-old boy with *Aspergillus fumigatus* endocarditis after surgical correction of tetralogy of fallot was another similar case presented by Miranda et al from Portugal (12). As shown, the antemortem diagnosis of *Aspergillus fumigatus* endocarditis is possible in one out of four pediatric patients (11). This matter demonstrated the value of current report as a successful diagnostic and also therapeutic case. Current paper revealed the importance of clinical suspicion by physicians in pediatric cases with current history of cardiothoracic surgeries for prompt diagnosis and successful treatment of *Aspergillus fumigatus* endocarditis.

### 4- CONCLUSION

Current paper revealed the importance of clinical suspicion by physicians in pediatric cases with current history of cardiothoracic surgeries for prompt diagnosis and successful treatment of *Aspergillus fumigatus* endocarditis.

**5- CONFLICT OF INTEREST:** None.

### 6- REFERENCES

1. Demaria RG, Dürrleman N, Rispaill P, Margueritte G, Macia JC, Aymard T, et al. *Aspergillus flavus* mitral valve endocarditis after lung abscess. *J Heart Valve Dis* 2000; 6: 786-90.
2. Saxena P, Clarke B, Dunning J. *Aspergillus* endocarditis of the mitral valve in a lung-transplant patient. *Tex Heart Inst J* 2007; 34: 95-7.

3. Gori F, Nesi G, Pedemonte E. Aspergillus fungus balls on the mitral valve. *N Engl J Med* 2001; 344: 310-11.
4. Yuan SM. Right-sided infective endocarditis: recent epidemiologic changes. *Int J ClinExp Med*. 2014; 7: 199-218.
5. Johnson JA, Boyce TG, Cetta F, Steckelberg JM, Johnson JN. Infective endocarditis in the pediatric patient: a 60-year single-institution review. *Mayo Clin Proc* 2012; 87: 629-35.
6. Day MD, Gauvreau K, Shulman S, Newburger JW. Characteristics of children hospitalized with infective endocarditis. *Circulation* 2009; 119: 865-70.
7. Abuzaid AA, Zaki M, Tarif H. Atypical early Aspergillus endocarditis post prosthetic mitral valve repair: a Case Presentation. *Heart Views*. 2015; 16: 30-3.
8. Pierrotti LC, Baddour LM. Fungal endocarditis 1995-2000. *Chest*. 2002; 122: 302-310.
9. Leong R, Gannon BR, Childs TJ, Isotalo PA, Abdollah H. Aspergillus fumigatus pacemaker lead endocarditis: a Case Presentation and review of the literature 2006; 22: 337-40.
10. Pemán J, Ortiz R, Osseyran F, Pérez-Bellés C, Crespo M, Chirivella M, et al. Native valve Aspergillus fumigatus endocarditis with blood culture positive and negative for galactomannan antigen. Case Presentation and literature review. 2007; 24: 157-60.
11. Barst RJ, Prince AS, Neu HC. Aspergillus endocarditis in children: Case Presentation and review of the literature 1981; 68: 73-8.
12. Miranda JO, de Sousa AR, Monterroso J. Aspergillus endocarditis in a paediatric patient after a cardiac surgery, associated with septic pulmonary embolism and pulmonary hypertension 2015; 25: 563-65.